IN THE HIGH COURT OF THE REPUBLIC OF SINGAPORE

[2019] SGHC 274

Suit No 463 of 2017

Between

Goh Guan Sin (by her litigation representative Chiam Yu Zhu)

… *Plaintiff*

And

(1) Yeo Tseng Tsai
(2) National University Hospital (Singapore) Pte Ltd

… *Defendants*

JUDGMENT

[Tort] — [Negligence] — [Breach of duty]

Version No 1: 27 Oct 2020 (22:41 hrs)

TABLE OF CONTENTS

FACTS **2**

DIAGNOSIS OF THE TUMOUR 2

CONSULTATIONS AT NUH 4

TUMOUR REMOVAL SURGERY AT NUH (THE FIRST SURGERY) 5

POST-OPERATIVE DEVELOPMENTS 6

THE PARTIES' CASES **10**

THE PLAINTIFF'S CASE 10

THE FIRST DEFENDANT'S CASE 14

THE SECOND DEFENDANT'S CASE 18

COUNTERCLAIM AND DEFENCE TO COUNTERCLAIM 20

MY DECISION **21**

ISSUES TO BE DETERMINED 22

PRE-OPERATIVE STAGE **23**

THE PLAINTIFF'S INFORMED CONSENT FOR THE FIRST SURGERY 23

Relevant and material information must be disclosed to the patient *24*

Risks of the First Surgery *25*

(1) The Plaintiff and her family were informed of the risks of the First Surgery 28

(2) Risk of post-operative haemorrhage 30

Strategy for managing post-operative haemorrhage *32*

Identity of the surgeon who would perform the First Surgery *33*

(1) The 15 May 2014 Consultation 34

(2) The 29 May 2014 Consultation 38

Version No 1: 27 Oct 2020 (22:41 hrs)

The First Defendant's availability after the Second Surgery.....*41*

Causation for pre-operative stage *42*

WHETHER THE FIRST DEFENDANT SHOULD HAVE PERSONALLY REVIEWED THE PLAINTIFF BEFORE THE DATE OF THE FIRST SURGERY.....43

CONCLUSION ON NEGLIGENCE ALLEGED AT THE PRE-OPERATIVE STAGE.....47

POST-OPERATIVE STAGE.....49

CAN MEDICAL FACTUAL WITNESSES GIVE EXPERT OPINIONS ON MEDICAL PRACTICE THAT ARE WITHIN THEIR DOMAIN OF PROFICIENCY?.....50

THE LAW ON MEDICAL NEGLIGENCE.....55

POST-OPERATIVE MONITORING AND CARE OF THE PLAINTIFF.....60

Failure to record all neurological observations in a single document....*60*

Monitoring of the Plaintiff's condition after the First Surgery.....*64*

(1) Adequacy of direction for hourly monitoring 65

(2) Was the Second Defendant negligent because it failed to take the Plaintiff's neurological parameters at 1610 hrs?.....68

(3) The First Defendant's liability for any failure to monitor.....73

What should have been done at 1655 hrs and 1730 hrs? *77*

(1) Plaintiff's condition at 1655 hrs.....77

(a) Whether a doctor was alerted *77*

(B) Should a CT Scan have been done at 1655 hrs?.....*80*

(2) Plaintiff's condition at 1730 hrs.....83

INTERPRETATION OF THE FIRST CT SCAN 92

Introduction and overview *92*

The experts' opinions *98*

(1) Plaintiff's experts 101

(2) Defendants' experts.....108

Discussion and findings *114*

(1) The location of the Plaintiff's pons.....114

Version No 1: 27 Oct 2020 (22:41 hrs)

(2) Plaintiff's clinical presentation just before the Second Surgery 129

(3) Radiological features on the First CT Scan.....132

(4) My findings on the interpretation of the First CT Scan 141

DECISION TO INSERT AN EVD AS THE SOLE SURGICAL RESPONSE 145

Case A: Intra-axial pontine haematoma.....147

(1) The Plaintiff's prognosis.....147

(A) The Caplan textbook, the Jee Article, the Chua and Kong Article and the Tator Article 150

(B) The Behrouz article and Huang's table 154

(2) The expert's evidence on the proper course of treatment 158

(3) My assessment of the First Defendant's approach to treatment160

Case B: Entirely extra-axial haematoma.....166

(1) The Plaintiff's prognosis.....166

(2) My assessment of the First Defendant's approach to treatment169

ALLEGATIONS IN RELATION TO THE SECOND SURGERY.....171

Informed consent for the Second Surgery 172

Option to evacuate the haematoma.....175

Failure to perform the Second Surgery personally.....176

CONCLUSION ON NEGLIGENCE ALLEGED AT THE POST-OPERATIVE STAGE...178

CAUSATION.....180

OMISSION TO RECORD NEUROLOGICAL PARAMETERS AT 1610 HRS 184

NOT ORDERING A CT SCAN AT 1655 HRS OR 1730 HRS.....185

FAILURE TO ADVISE ON THE OPTION OF EVACUATING THE HAEMATOMA.....187

FAILURE TO EVACUATE THE EXTRA-AXIAL COMPONENT OF THE HAEMATOMA 187

ALTERNATIVE CAUSATION ANALYSIS FOR EVACUATION OF HAEMATOMA IF THE HAEMATOMA HAD BEEN ENTIRELY OR SUBSTANTIALLY EXTRA-AXIAL.....188

Version No 1: 27 Oct 2020 (22:41 hrs)

Upward herniation theory *190*

Venous infarct theory *192*

My assessment of the new haemorrhages *197*

CONCLUSION ON CAUSATION 199

FRACTURE SUFFERED BY THE PLAINTIFF 200

THE SECOND DEFENDANT'S COUNTERCLAIM 207

CONCLUSION 207

Version No 1: 27 Oct 2020 (22:41 hrs)

This judgment is subject to final editorial corrections approved by the court and/or redaction pursuant to the publisher's duty in compliance with the law, for publication in LawNet and/or the Singapore Law Reports.

Goh Guan Sin (by her litigation representative Chiam Yu Zhu)
v
Yeo Tseng Tsai and another

[2019] SGHC 274

High Court — Suit No 463 of 2017
Tan Siong Thye J
17–18, 23–26, 30 April, 2–3, 7–10, 14–16, 21–22 May, 8–12, 16–19 July, 5–6, 13 August; 8–9 October 2019

27 November 2019 Judgment reserved.

Tan Siong Thye J:

1 This is a medical negligence case involving a 70-year-old patient, Mdm Goh Guan Sin ("the Plaintiff"), who has been in a persistent vegetative state ("PVS") since June 2014 after undergoing surgery to remove a brain tumour.[1] The surgery was performed by Dr Yeo Tseng Tsai ("the First Defendant"), a senior consultant and the Head of the Division of Neurosurgery at the National University Hospital ("NUH"). NUH is managed by the National University Hospital (Singapore) Pte Ltd ("the Second Defendant"). The Plaintiff filed this suit through her litigation representative, PW1 Ms Chiam Yu Zhu ("PW1 Ms Chiam"), who is one of her daughters and her deputy. The Plaintiff commenced the suit against the First Defendant and

---

1 Agreed Statement of Facts ("ASOF") at S/N 2.

the Second Defendant (collectively referred to as the "Defendants") on allegations of negligence before, during, and after the surgery. However, when the trial started, the Plaintiff decided not to pursue her claims for negligence during the surgery. At the end of the trial, the Plaintiff further dropped her allegations of negligence at the pre-operative stage. She now focuses her case of negligence against the Defendants for their failure to care and manage her after the surgery. The Second Defendant counterclaims for unpaid hospital bills.

Facts

Diagnosis of the tumour

2 On 24 April 2014, PW1 Ms Chiam brought the Plaintiff to see an orthopaedic doctor at NUH as the Plaintiff had been experiencing frequent falls due to difficulty in balancing herself. The Plaintiff was advised to have a magnetic resonance imaging ("MRI") scan done.

3 On 2 May 2014, the Plaintiff, accompanied by another daughter, Ms Chiam Li Ling ("Li Ling"), went for a brain MRI scan at RadLink Diagnostic Imaging (S) Pte Ltd ("the RadLink MRI"). The RadLink MRI showed that the Plaintiff had a large tumour and hydrocephalus.[2] Hydrocephalus is a condition that involves an increase in intracranial pressure due to excessive cerebrospinal fluid ("CSF") accumulation in the four ventricles of the brain. The ventricles produce CSF, which is a clear, colourless fluid that circulates in the brain to protect vital brain components from trauma. CSF is also found in the spinal cord.

---

2 ASOF at S/N 5.

Version No 1: 27 Oct 2020 (22:41 hrs)

4 It is not disputed that the Plaintiff was correctly diagnosed with a left cerebellopontine angle tumour (vestibular schwannoma (VS), also known as acoustic neuroma). The tumour was benign and slow-growing. Eventually it reached a size of 4.9cm x 3.7cm x 3.5cm as of 2 May 2014.[3] The tumour compressed the brainstem (which comprises the midbrain, pons and medulla in descending order in a roughly columnar shape)[4] at the level of the pons, as well as other parts of the brain. Prolonged compression by the growing tumour had distorted the shape, size and location of the pons significantly, though the precise extent is disputed by the parties. The tumour also pressed against the cerebellum and the fourth ventricle. The tumour developed on the vestibular and cochlear nerves leading from the inner ear to the brain. The location of the tumour is shown in the diagram[5] below:

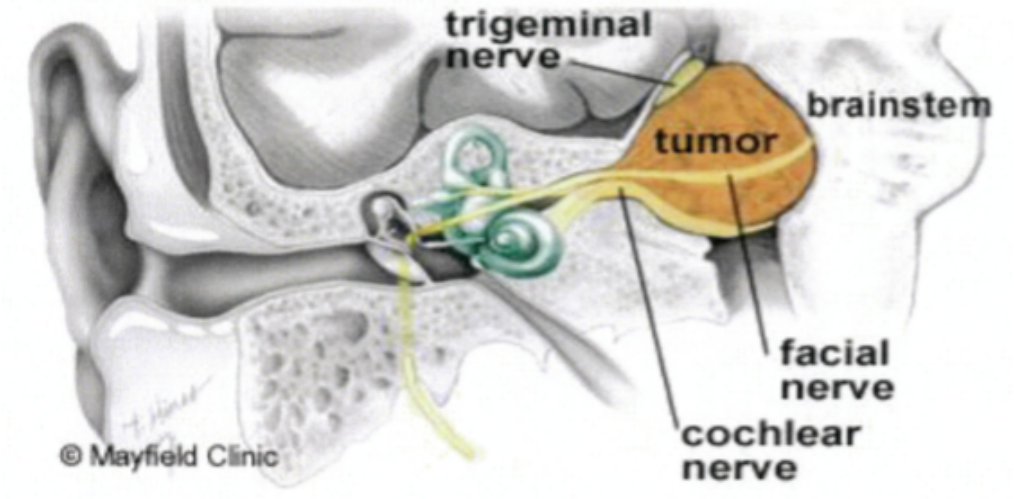

[3] Agreed Medical Facts at S/N 1.

[4] Agreed Medical Facts at S/N 1; Agreed Glossary of Medical Terms ("AGMT") at S/N 5.

[5] Diagrams referred to in AGMT, diagram 16B.

Version No 1: 27 Oct 2020 (22:41 hrs)

5 The tumour had to be removed to prevent further brain damage. This is a serious and a major surgery that carries other risks, including the risk of death. The Plaintiff and her children wanted a second opinion.

6 On 10 May 2014, the Plaintiff, accompanied by PW1 Ms Chiam and another daughter, Ms Chiam Yin Mee ("Carol"), consulted Dr Timothy Lee ("Dr Lee"), a neurosurgeon at Gleneagles Hospital. Dr Lee confirmed that the Plaintiff had a tumour which had to be removed.

Consultations at NUH

7 After consulting Dr Lee, the Plaintiff, accompanied by PW1 Ms Chiam and Li Ling, sought another opinion at NUH on 15 May 2014 ("the 15 May 2014 Consultation"). The doctor who attended to the Plaintiff was DW9 Dr Ho Kee Hang ("DW9 Dr Ho"), a neurosurgeon who is a visiting consultant at NUH.[6] DW9 Dr Ho also practises neurosurgery at Mount Elizabeth Medical Centre. At this consultation, DW15 Dr Gabriel Lu Yeow Yuen ("DW15 Dr Lu") and DW6 Dr Ng Zhi Xu ("DW6 Dr Ng") were in attendance. The parties dispute what transpired at the 15 May 2014 Consultation. In any event, it was on 15 May 2014 that surgery to remove the tumour was scheduled for 2 June 2014 ("the First Surgery") and a second consultation was scheduled for 29 May 2014 ("the 29 May 2014 Consultation").

8 On 22 May 2014, the Plaintiff, accompanied by PW1 Ms Chiam and Carol, sought another opinion from Dr James Khoo ("Dr Khoo"), a neurosurgeon at Mount Elizabeth Medical Centre. The Plaintiff was prescribed with Diamox, as she had complained of headaches. She was also diagnosed with

---

6 ASOF at S/N 6.

Version No 1: 27 Oct 2020 (22:41 hrs)

ataxia, which refers to the lack of muscle coordination resulting in, *inter alia*, gait abnormality.[7] Also on this day, though unbeknownst to the Plaintiff at that time, the Plaintiff's case was discussed at the NUH's Division of Neurosurgery's weekly peer review pre-operative discussion ("the Department Meeting"). According to the First Defendant, it was at this meeting that he agreed to DW9 Dr Ho's request to perform the First Surgery.[8]

9 On 26 May 2014, PW1 Ms Chiam brought the Plaintiff to the Accident and Emergency ("A&E") department at NUH as the Plaintiff was unwell. Coincidentally, this was also the day when PW1 Ms Chiam received a call from NUH about the Plaintiff's next appointment at NUH. Following the clarifications made by Carol with NUH, the siblings realised that an appointment was scheduled for the Plaintiff to consult the First Defendant on 27 May 2014. The Plaintiff did not attend this consultation.[9]

10 On 29 May 2014, the Plaintiff returned to NUH for her appointment and was attended to by DW6 Dr Ng, a resident at NUH at the material time. As with the 15 May 2014 Consultation, the parties' accounts of what happened during the 29 May 2014 Consultation differ.

Tumour removal surgery at NUH (the First Surgery)

11 Thereafter, on 1 June 2014 at around 1736 hrs, the Plaintiff was admitted to NUH as a Class B1 private paying patient to prepare for the First Surgery the following day. At around 2100 hrs, DW15 Dr Lu, then a registrar in NUH,

---

7 Defendants' Bundle of Documents ("DBOD") at pp 412–413.

8 Dr Yeo's AEIC at paras 10–11.

9 PW1 Chiam Yu Zhu's AEIC at para 34.

Version No 1: 27 Oct 2020 (22:41 hrs)

attended to the Plaintiff and obtained the Plaintiff's signature on the consent form for the First Surgery.[10]

12 On 2 June 2014 at around 0800 hrs, the Plaintiff was wheeled into the operating theatre. This was the first time that the Plaintiff was seen by the First Defendant.[11] The First Surgery started at 0947 hrs. The First Defendant was assisted by two other consultant neurosurgeons, DW11 Dr Pang Boon Chuan ("DW11 Dr Pang") and DW12 Dr Low Shiong Wen ("DW12 Dr Low"). In the course of the First Surgery, the superior petrosal vein ("SPV") was sacrificed in order to access the tumour. The SPV is a vein or venous complex that drains blood from the cerebellum and brainstem into the superior petrosal sinus.[12] A portion of the tumour capsule could not be removed as it was densely adherent to the brainstem. The First Surgery was uneventful and concluded at 1415 hrs.

Post-operative developments

13 After the First Surgery, the Plaintiff was transferred to the recovery room, also known as the post-acute care unit or PACU, at 1452 hrs. There, it was documented that the Plaintiff had a Glasgow Coma Scale ("GCS") score of 15, the best possible score, at 1505 hrs, 1510 hrs, 1520 hrs, 1535 hrs, 1550 hrs, 1605 hrs and 1620 hrs.[13] The GCS is an accepted scoring system for measuring a patient's consciousness level. It comprises three components that check for the patient's best eye opening response, best motor response, and best verbal response. The maximum score for each component is 4, 6 and 5 respectively,

---

10 ASOF at S/N 10.

11 ASOF at S/N 11.

12 AGMT at S/N 46.

13 Agreed Table of Observations ("ATO").

Version No 1: 27 Oct 2020 (22:41 hrs)

giving a best possible score of 15 (*ie*, E4 M6 V5) which indicates that a patient has no apparent neurological deficit. The lowest possible GCS score is 3, which signifies deep coma or brain death.[14] The scoring chart for GCS is as follows.

PARAMETER	PATIENT RESPONSE	SCORE
Best eye opening response (record "C" if eyes closed because of swelling)	Spontaneously	4
	To speech	3
	To pain	2
	No response	1
Best motor response (record best upper limb response to painful stimuli)	Obeys verbal command	6
	Localizes pain	5
	Flexion—withdrawal, purposeless movement	4
	Flexion—abnormal	3
	Extension—abnormal	2
	No response (flaccid)	1
Best verbal response (record "E" if endotracheal tube is in place or "T" if tracheostomy tube is in place)	Conversation—oriented × 3	5
	Conversation—confused	4
	Speech—inappropriate	3
	Sounds—incomprehensible	2
	No response	1
TOTAL SCORE (SUM OF SCORES FOR EACH OF THE THREE GROUPS)	**INTERPRETATION**	
15	Normal	
13-15	Minor head injury	
9-12	Moderate head injury	
3-8	Severe head injury	
≤7	Coma	
3	Deep coma or brain death	

14 At 1655 hrs, the Plaintiff was transferred to the High Dependency Unit ("HDU") Ward 25. It was recorded by a nurse, DW14 Ms Lee Sok Gin ("DW14 Nurse Lee"), that the Plaintiff's GCS at 1655 hrs was 13 (E4 V3 M6) and that there was a complete lack of motor power over her right limbs (*ie*, her motor power for both right limbs was 0 out of 5).[15] In other words, the Plaintiff had

[14] AGMT at S/N 70; Diagrams referred to in AGMT, diagram 20.

[15] First and Second Defendants' Bundle of Documents ("DBD") at p 84.

Version No 1: 27 Oct 2020 (22:41 hrs)

right hemiplegia, which refers to the paralysis of the right side of the body.[16] I note here that there is no contradiction between scoring M6 for GCS (*ie*, a perfect motor component score) and right hemiplegia under the motor score. The former assesses the *best* motor response in terms of whether the patient understands what is being said and obeys commands, while the latter assesses motor movement of *each* limb. Hence, if a patient is hemiplegic but can use the limbs on the other side of the body to obey commands, that warrants a score of M6 for GCS[17] but will be reflected as zero power on one side of the body for motor score.

15 The Plaintiff was then reviewed by DW15 Dr Lu together with DW5 Dr Yang Ming ("DW5 Dr Yang") at 1730 hrs. The Plaintiff's GCS, as recorded at 1730 hrs, was 15. The Plaintiff was noted to be able to move all four limbs, although there was weakness on the right side. The motor power recorded for the right upper and lower limbs were 3 and 1 respectively.[18] The motor power of her left limbs was normal for her, this being a score of 4 out of 5 due to pre-existing weakness of her left leg.[19] The Plaintiff was observed to be alert.

16 At about 1805 hrs, the Plaintiff's GCS declined to 12. The Plaintiff was reviewed again by DW5 Dr Yang at 1820 hrs. It was noted that her level of consciousness had deteriorated rapidly with right-sided weakness in her limbs. Her GCS score was recorded as 10 with motor power of 0 out of 5 for her right upper and lower limbs. The Plaintiff's blood pressure was 200/90 mmHg, her

---

16 AGMT at S/N 78.

17 25/4/19 NE 37-39.

18 DBD at p 77.

19 DBD at p 12.

Version No 1: 27 Oct 2020 (22:41 hrs)

heart rate was 55 bpm and she was experiencing laboured breathing. In other words, the Plaintiff was exhibiting signs of Cushing reflex, which is a nervous system response to critically elevated intracranial pressure. The symptoms for Cushing reflex are increased blood pressure, irregular breathing, and abnormally slow heart action (bradycardia).[20] Cushing reflex is very serious and will lead to death if untreated.

17 An urgent computed tomography ("CT") brain scan was carried out at 1829 hrs ("the First CT Scan").[21] The parties hotly contest the correct interpretation of the First CT Scan. It suffices here to state that the First Defendant decided, based on his interpretation of the First CT Scan, to insert an external ventricular drain ("EVD") in the Plaintiff's brain to relieve the acute hydrocephalus. PW1 Ms Chiam signed the consent form for this procedure. The EVD was inserted by Dr Mohammad Rashidul Hassan ("Dr Rashidul"), under the First Defendant's supervision, at around 1925 hrs on 2 June 2014 ("the Second Surgery"). Dr Rashidul was not called in these proceedings. The Second Surgery concluded at 1945 hrs.[22]

18 A second CT scan was performed at around 2013 hrs and it is not disputed that this scan showed haemorrhage (*ie*, bleeding) in the brainstem ("the Second CT Scan").

19 At around 2015 hrs, the First Defendant introduced himself to the Plaintiff's family. He informed them that the Plaintiff had developed a haematoma (*ie*, a blood clot) at the site of the initial surgery and that an EVD

---

20 AGMT at S/N 66.

21 ASOF at S/N 16.

22 ASOF at S/N 18–19.

Version No 1: 27 Oct 2020 (22:41 hrs)

had been inserted. The First Defendant also informed the Plaintiff's family that regardless of whether the haematoma was surgically evacuated or conservatively managed, the Plaintiff would have an equally poor prognosis and thus be likely to end up in a PVS or comatose state.[23]

20 Following the events on 2 June 2014, the Plaintiff suffered irreversible brain damage and is now in a PVS. She depends on ventilator support and will require lifelong care.[24] The Plaintiff remains a patient at NUH to this day.

The parties' cases

The Plaintiff's case

21 The Plaintiff's allegations of negligence were initially confined to the *pre-operative* and *post-operative* stages. At the close of the trial, the Plaintiff abandoned her action against the Defendants for pre-operative negligence. Nevertheless, I shall state the Plaintiff's case for pre-operative negligence.

22 At the pre-operative stage, the Plaintiff alleges that the First Defendant breached his duty of care to her for these reasons:[25]

> (a) The First Defendant failed to obtain the Plaintiff's informed consent for the First Surgery because he had not provided adequate information to her regarding the intra- and post-operative risks of the First Surgery. In particular, he had not told her that "bleeding is the commonest complication of a cystic VS [*ie*, vestibular schwannoma]

---

23 ASOF at S/N 21.

24 ASOF at S/N 22.

25 Statement of Claim (Amendment No 2) ("SOC") at paras 40A-C.

Version No 1: 27 Oct 2020 (22:41 hrs)

and is known to have increased risk of post-operative bleeding". He also failed to present to the Plaintiff the range of options available for her appropriate management, including advising on his "management plans and strategy in the event of post-operative bleeding, including careful and vigilant monitoring of her condition by the [First] Defendant and by the [Second] Defendant and its servants and/or agents at acceptable intervals so that appropriate and timely intervention [can] be carried out".

(b) The First Defendant failed to personally review the Plaintiff's case through good history-taking and appropriate clinical examination and did not:

(i) personally see the Plaintiff to inform her he would be taking over from DW9 Dr Ho and confirm the diagnosis for which surgical care was proposed; or

(ii) inform the Plaintiff that he would be leaving the country the day after the surgery and tell her of a surgeon who would be taking over her post-operative management in his absence.

23 In relation to the above, the Plaintiff also alleges that the Second Defendant similarly breached its duty of care to her (under an express or implied term of the agreement with the Plaintiff, or a tortious duty of care) and was vicariously liable for any breaches on the part of the First Defendant.[26]

---

[26] SOC at paras 4–7.

Version No 1: 27 Oct 2020 (22:41 hrs)

24 At the post-operative stage, the Plaintiff alleges that the First Defendant was negligent because:[27]

(a) The First Defendant misinterpreted the First CT Scan and diagnosed the haematoma (*ie*, blood clot) as an intra-axial one in the brain substance rather than an extra-axial one outside the brain substance. In particular, he did not compare the First CT Scan with the RadLink MRI.

(b) The First Defendant failed to evacuate the Plaintiff's extra-axial haematoma to address the severe brainstem compression arising therefrom, which consigned her to a PVS.

(c) The First Defendant failed to obtain the Plaintiff's informed consent for inserting the EVD and did not advise on the option of evacuating the extra-axial haematoma.

25 The Plaintiff alleges that the Second Defendant was, in addition to being vicariously liable for the First Defendant's breaches, also negligent at the post-operative stage because:[28]

(a) The Second Defendant failed to adequately monitor the Plaintiff's neurological parameters and clinical condition post-operatively.

---

27 SOC at paras 40D–N; Plaintiff's closing submissions ("PCS") at para 3.

28 PCS at para 2.

Version No 1: 27 Oct 2020 (22:41 hrs)

(b) The Second Defendant failed to carry out a CT scan urgently when the Plaintiff was observed by DW14 Nurse Lee at the HDU to have complete right-sided weakness and a GCS of 13 at 1655 hrs.

(c) The Second Defendant failed to implement a proper system to ensure that critical neurological parameters were recorded in a manner that made the Plaintiff's neurological trends available to every successive doctor who dealt with the Plaintiff.

26 The above breaches by the Defendants allegedly "caused or materially contributed" to the Plaintiff's PVS; alternatively these resulted in a "loss of chance" for the Plaintiff to obtain a better medical outcome.[29]

27 Separately, the Plaintiff alleges that the Second Defendant failed to take reasonable care of her post-operatively while she was in a PVS in the HDU, causing her to suffer a fractured right knee (right tibial tuberosity).[30] She pleaded *res ipsa loquitur* to establish negligence and breach of duty of care.[31]

28 The Plaintiff, initially, also alleged that: (a) she was symptomatic of hydrocephalus which the First Defendant ought to have addressed through a EVD or shunt before the First Surgery; and (b) the Second Defendant's negligence caused her left middle finger to swell and her fingernail to fall off, as well as a 2mm cut on her neck that had to be stitched up. These claims were later withdrawn at the start of the trial.[32]

---

29 PCS at para 4.

30 SOC at para 46(xiii).

31 SOC at para 44.

32 23/4/19 NE 64; 7/5/19 NE 163.

Version No 1: 27 Oct 2020 (22:41 hrs)

29 The Plaintiff called the following experts:

(a) PW3 Dr Peter Gan ("PW3 Dr Gan"), a clinical director and consultant neurosurgeon at Waikato Hospital in New Zealand;

(b) PW5 Dr Tang Kok Kee ("PW5 Dr Tang"), a consultant neurosurgeon at Mount Elizabeth Novena Specialist Centre;

(c) PW2 Dr Chua Gim Chuah ("PW2 Dr Chua"), a senior consultant radiologist at Gleneagles Hospital; and

(d) PW4 Dr Pay Khim Hui ("PW4 Dr Pay"), a consultant radiologist at Gleneagles Hospital.

The First Defendant's case

30 The First Defendant accepts that he owed the Plaintiff a duty of care to provide appropriate, reasonable and sound medical advice and treatment.[33] However, he denies that he breached this duty.

31 At the pre-operative stage, his contention is that:

(a) He had conducted adequate pre-operative assessment of the Plaintiff. He had read the RadLink MRI, attended the Department Meeting where the Plaintiff's case was discussed, reviewed the Plaintiff's case notes beforehand and personally assessed the Plaintiff in the operating theatre before she was anaesthetised for the First Surgery.[34]

---

33 First Defendant's Defence (Amendment No 3) ("FDD") at para 5.

34 FDD at para 37.

Version No 1: 27 Oct 2020 (22:41 hrs)

(b) DW9 Dr Ho had told the Plaintiff as early as the 15 May 2014 Consultation that he would not be performing the surgery and that the First Defendant would either perform the surgery himself or appoint a neurosurgeon in the department to do so.[35] The Plaintiff and PW1 Ms Chiam were again informed by DW6 Dr Ng at the 29 May 2014 Consultation that DW9 Dr Ho would not be the surgeon operating on the Plaintiff. On 1 June 2014, the night before the First Surgery, DW15 Dr Lu reiterated that DW9 Dr Ho would not be the surgeon for the Plaintiff.[36] The Plaintiff was also informed at the latter two consultations, *ie*, 29 May 2014 and 1 June 2014, that the First Defendant would be the surgeon.

(c) While the First Defendant only managed to see the Plaintiff in the operating theatre on the day of the First Surgery, this was because the Plaintiff failed to attend the scheduled consultation with him on 27 May 2014.[37] In any case, in the operating theatre, the First Defendant personally assessed her, told her of the nature and risks of the First Surgery and obtained her consent.[38] Further, he informed the Plaintiff's family on 3 June 2014 that he would be away from Singapore from 4 June 2014 onwards and that Dr Sein Lwin and Assoc Prof Chou Ning would take care of the Plaintiff in his absence.[39]

---

35 FDD at para 11a.

36 FDD at paras 11i(ii) and 14.

37 FDD at para 11g.

38 FDD at para 37c.

39 FDD at para 34.

Version No 1: 27 Oct 2020 (22:41 hrs)

(d) Regarding the taking of consent, the Second Defendant, as a public healthcare institution, operates on a system of team-based care.[40] This involved a consultant (here, the First Defendant) assuming overall responsibility for the patient (the Plaintiff), with the care of the patient undertaken by other doctors in the team.[41] This includes consent-taking and pre-and post-operative review. There were three occasions before the First Defendant's own taking of consent in the operating theatre where the risks, including haemorrhage in the brain, were explained and/or consent obtained, namely: (i) the 15 May 2014 Consultation with DW9 Dr Ho, (ii) the 29 May 2014 Consultation with DW6 Dr Ng, and (iii) the 1 June 2014 consultation with DW15 Dr Lu.[42]

32 The First Defendant also denies that he was negligent in respect of post-operative care and contends that:

(a) He had personally reviewed the Plaintiff at the recovery room after the First Surgery and noted that she was well and alert with her facial nerve fully intact.[43] Subsequently, he was unable to be personally involved because he was in the operating theatre performing a surgery on another patient which ended at or around 1830 hrs.

(b) The doctors and nurses of the Second Defendant adequately monitored the Plaintiff after the First Surgery. The Plaintiff was not unresponsive after the First Surgery, but was observed by the nursing

---

40 FDD at para 5a.

41 First Defendant's opening statement at para 27.

42 FDD at paras 11c, 11i, 13b, 19c.

43 FDD at para 22b.

Version No 1: 27 Oct 2020 (22:41 hrs)

staff to be fully conscious and able to obey commands. Her GCS was 15 between 1505 hrs and 1620 hrs.[44] The Plaintiff was reviewed at 1730 hrs by DW15 Dr Lu and DW5 Dr Yang, who informed the Plaintiff's family that the Plaintiff was stable and was able to move and talk, in spite of a weakness on the right side of the body.[45] It was only at 1820 hrs when the Plaintiff's GCS had decreased to 10 and the motor power of her right limbs had deteriorated to 0/5, that it became necessary to order the First CT Scan on an urgent basis.

(c) He had correctly read the First CT Scan, together with DW11 Dr Pang and DW12 Dr Low, to conclude that there was haemorrhage in the operative site which extended to the brainstem (specifically, the pons) as well as acute hydrocephalus due to the brainstem haemorrhage.[46]

(d) The Plaintiff's prognosis was poor as she had an intra-axial haematoma in the brainstem. In addition, the Plaintiff was comatose and her GCS recorded just before the Second Surgery at 1850 hrs was 3, which is the lowest possible score.[47] It would not have improved her condition to remove the intra-axial haematoma, or the extra-axial haematoma along the surgical tract. The Second Surgery was done to relieve her acute hydrocephalus.[48] The Plaintiff's poor prognosis, therefore, did not justify the risks of evacuating the haematoma, which

---

44 FDD at para 22a.

45 FDD at para 22d.

46 FDD at 37h.

47 ATO at p 2.

48 FDD at para 37i.

Version No 1: 27 Oct 2020 (22:41 hrs)

might damage the cerebellum, brainstem and cranial nerves and carried a high risk of death.[49]

(e) The haemorrhage in the pons was a rare complication arising from the ligation and sacrifice of the SPV during the First Surgery, which resulted in venous infarction (*ie*, tissue death) of the pons. The upward herniation of the Plaintiff's brainstem after the insertion of the EVD was not significant and the haemorrhage in the brainstem was not Duret haemorrhage.[50]

(f) He did not owe the Plaintiff's family a duty of care to advise them on the alternative options to manage the post-operative haematoma.[51]

33 The First Defendant also denies that causation is made out even if he were in breach of duty and denies that the Plaintiff is entitled to rely on *res ipsa loquitur* for the injuries she sustained during her hospitalisation after the First Surgery.[52]

The Second Defendant's case

34 The Second Defendant accepts that it was under a duty of care in tort[53] to provide medical and nursing care, treatment and advice in accordance with

---

49 14/5/19 NE 151–152.

50 FDD at para 33.

51 FDD at para 37n.

52 FDD at paras 43–44.

53 Second Defendant's closing submissions ("D2CS") at para 48.

Version No 1: 27 Oct 2020 (22:41 hrs)

the proper standard of care[54] but it denies it was negligent. Because its case is essentially aligned with that of the First Defendant, it is not necessary to outline it separately save for two aspects.

35 Firstly, the Second Defendant has a counterclaim for outstanding hospital bills incurred by the Plaintiff, these being $397,478.78 as of 26 July 2019 and the Plaintiff's further bills from 27 July 2019 to the date of judgment.[55]

36 Secondly, the Second Defendant alleges it was not negligent in causing the Plaintiff to suffer a fracture in 2016. On 18 August 2016, one of the Plaintiff's daughters had requested for an X-ray to be conducted on both the Plaintiff's legs. This was done promptly the next day, 19 August 2016. The X-ray showed a mildly displaced fracture at the right tibial tuberosity. Degenerative changes of the right knee joint were also noted. An orthopaedic doctor had reviewed the Plaintiff on the same day and stated that the fracture looked old and was already healing. It was explained to the Plaintiff's family on the same day that there were two treatment options: surgery or conservative treatment with a ranger brace. The Plaintiff's family opted for conservative treatment with a ranger brace.[56] The Second Defendant adds that the cause of the Plaintiff's fracture could not be conclusively determined. There was no reported history of trauma or falls. Furthermore, the Plaintiff is osteopenic (*ie*, has decreased bone density) and is therefore at risk of sustaining fractures.[57]

---

54 Second Defendant's Defence & Counterclaim of the Second Defendant (Amendment No 2) ("SDDCC") at para 7.

55 SDDCC at paras 82–94.

56 SDDCC at paras 63–64.

57 SDDCC at para 65.

Version No 1: 27 Oct 2020 (22:41 hrs)

37 The Defendants' experts were:

(a) DW3 Dr Alvin Hong ("DW3 Dr Hong"), a neurosurgeon at Mount Elizabeth Medical Centre;

(b) DW4 Dr Ivan Ng ("DW4 Dr Ivan Ng"), a neurosurgeon at Mount Elizabeth Novena Specialist Centre;

(c) DW10 Dr Yeh Ing Berne ("DW10 Dr Yeh"), a neuro-radiologist at Lifescan Imaging Pte Ltd; and

(d) DW16 Dr Yu Wai-Yung ("DW16 Dr Yu"), a neuro-radiologist at the National Neuroscience Institute.

Counterclaim and defence to counterclaim

38 In the latest amended version of its counterclaim, the Second Defendant avers that the outstanding hospital bills for the medical treatment and care provided by the Second Defendant to the Plaintiff amount to S$397,478.78 as of 26 July 2019 and these continues to be incurred.[58] The Plaintiff and her family have not made full payment of the outstanding hospital bills. Furthermore, according to the Second Defendant, the Plaintiff's condition was assessed to be stable and fit for discharge to a stepdown care facility in or around October 2014. This was communicated to the Plaintiff's family in late February 2015.[59] However, the Plaintiff's family repeatedly rejected the Second Defendant's suggested care plans and refused to engage with them. Accordingly, the Second Defendant informed PW1 Ms Chiam on 27 July 2015 that it had no option but

---

58 SDDCC at para 92.

59 SDDCC at para 84.

Version No 1: 27 Oct 2020 (22:41 hrs)

to initiate the social over-stayer policy ("the Policy"). This meant that the Plaintiff would not be eligible for government subsidies upon the Policy taking effect. The Policy was eventually initiated on 29 August 2015, although it was suspended on 29 February 2016 as the Plaintiff developed sepsis and required acute inpatient care. The Plaintiff's sepsis resolved in September 2016 and she was found stable and fit for discharge to a stepdown care facility thereafter.[60]

39 In response, the Plaintiff asserts that the negligence of the Defendants have caused the Plaintiff to be in a PVS, for which they are liable to pay all losses and expenses. Accordingly, the Plaintiff is not liable for the unpaid hospital bills, which she would in any event be entitled to set off against any damages awarded in her favour for the Defendants' negligence. Furthermore, the Plaintiff asserts that she was not fit for discharge as of 29 August 2015 and the Policy should not have been activated.[61]

My decision

40 During oral closing submissions, the Plaintiff's counsel confirmed that he was not pursing the allegations of negligence at the pre-operative stage. However, he added that this was not because the Plaintiff's case lacked merits, but because the claim for damages sought would ultimately be traceable to the post-operative issues. Therefore, even though the Plaintiff maintained that there were legitimate issues in relation to the pre-operative stage, it would not be productive for the court to go through those issues.[62]

---

60 SDDCC at paras 84–89.

61 Plaintiff's Reply and Defence (Amendment No 2) to Second Defendant's Counterclaim (Amendment No 2) at paras 64–74.

62 8/10/19 NE 111.

Version No 1: 27 Oct 2020 (22:41 hrs)

41 This does not seem to be an unequivocal relinquishment of the claim of negligence at the pre-operative stage. That said, I notice that the Plaintiff's counsel has not mentioned the pre-operative issues at all in his written and oral closing submissions, which supports the view that the Plaintiff has abandoned these issues.

42 I would like to mention that at the start of the trial the Plaintiff had dropped her allegations of negligence during the surgery. At the end of the trial, she discontinued her allegations of negligence at the pre-operative stage. She now focuses on her allegations of post-operative negligence. Considerable time and resources would have been saved if the Plaintiff had made up her mind early on which issues of negligence she wanted to pursue instead of going on a wild goose chase. Having heard the evidence, I find that the Plaintiff's true reason for not pursuing the allegations of negligence at the pre-operative stage is that she realised, after hearing the evidence and after the issues were thoroughly ventilated during the trial, the futility of this claim. I shall now explain why the Plaintiff has failed to establish a case of negligence at the pre-operative stage on a balance of probabilities, notwithstanding that she has withdrawn her case against the Defendants. I shall also analyse other issues at the post-operative stage. Let me first identify the various issues.

Issues to be determined

43 The main issues pertaining to the pre-operative stage are:

(a) whether the First Defendant obtained the Plaintiff's informed consent for the First Surgery; and

(b) whether the First Defendant breached his duty of care by failing to personally see the Plaintiff before the surgery.

Version No 1: 27 Oct 2020 (22:41 hrs)

44 The main issues pertaining to the post-operative stage are:

(a) whether the Defendants fell below the requisite standard of care in relation to the monitoring of the Plaintiff after the First Surgery;

(b) whether the First Defendant fell below the requisite standard of care in reaching his diagnosis that there was significant intra-axial pontine haemorrhage and, related to this, whether he fell below the requisite standard of care in deciding not to evacuate the haematoma;

(c) whether the First Defendant owed a duty to the Plaintiff's family to advise them about the option to remove the haematoma, and if so, whether he fell below the requisite standard of care in failing to do so;

(d) whether the Second Defendant fell below the requisite standard of care in its post-operative care of the Plaintiff after the Second Surgery, resulting in the fracture sustained in 2016; and

(e) if there was a breach in relation to the foregoing, whether that breach caused the Plaintiff to suffer the loss for which she now seeks recovery.

45 There is also the issue of the Second Defendant's counterclaim against the Plaintiff for the outstanding hospital charges, which is straightforward and undisputed.

Pre-operative stage

The Plaintiff's informed consent for the First Surgery

46 The Plaintiff alleges that her informed consent for the First Surgery was not obtained because:

Version No 1: 27 Oct 2020 (22:41 hrs)

(a) She was not informed about the risks of the First Surgery.

(b) She was not informed about the First Defendant's management plans and strategy in the event of post-operative haemorrhage in the brain.

(c) She was only informed on the night before the First Surgery that the First Defendant and not DW9 Dr Ho would operate on her.

(d) She was not informed that the First Defendant would be leaving Singapore on 4 June 2014, *ie*, two days after the First Surgery on 2 June 2014 and would not be able to provide post-operative care personally until he returned. There was a slight discrepancy between the parties whether it was one or two days after,[63] but that is inconsequential.

Relevant and material information must be disclosed to the patient

47 The applicable law is not in dispute. As stated in *Singapore Medical Council v Dr Lim Lian Arn* [2019] SGHC 172 ("*Lim Lian Arn*") at [48] and [50], and *Hii Chii Kok v Ooi Peng Jin London Lucien and another* [2017] 2 SLR 492 ("*Hii Chii Kok*") at [143] and [184], the first port of call is to ask if the information is relevant and material to the patient. This is to be assessed from the vantage point of the patient, having regard to the matters that he is reasonably likely to attach significance to in arriving at his decision to proceed with the proposed treatment. Next, the information must reasonably be in the possession of the doctor. A doctor may also be justified in withholding information in particular situations and if that is the case, no liability arises for non-disclosure. Ultimately, what has to be disclosed is largely "a matter of

63 SOC at para 40B(iii); 14/5/19 NE 16.

Version No 1: 27 Oct 2020 (22:41 hrs)

common sense". A reasonable patient would not need or want to know and understand every iota of information before deciding whether or not to undergo the proposed treatment. To overwhelm a patient with minute details will also not be helpful. The following types of information would typically be regarded as material (*Hii Chii Kok* at [138]):

(a) the doctor's diagnosis of the patient's condition;

(b) the prognosis of the patient's condition with and without medical treatment;

(c) the nature of the proposed medical treatment;

(d) the risks associated with the proposed medical treatment; and

(e) the alternatives to the proposed medical treatment and the attendant advantages and risks.

The broad types of material information identified by the Court of Appeal in *Hii Chii Kok* are not exhaustive. However, they are highly indicative of what a court would generally consider to be relevant and material information.

Risks of the First Surgery

48 The risks of the First Surgery are relevant and material as they fall within category (d) in *Hii Chii Kok*.

49 The discussion here focuses on whether the Plaintiff was informed of the risk of post-operative haemorrhage in the brain, because this was the risk

Version No 1: 27 Oct 2020 (22:41 hrs)

specifically pleaded by the Plaintiff.[64] While she pleaded more generally that the First Defendant "failed to advise and provide adequate information to [her] about the possible complications [and] risks" of the First Surgery,[65] such broad allegations are unsatisfactory. A plaintiff must "identify the exact nature of the information that he alleges was not given to him and establish *why* it would be regarded as relevant and material" (*Hii Chii Kok* at [132]) [emphasis in original].

50 I accept the Defendants' submissions that in a public hospital that practises team-based care, it is reasonable for other members of the operating surgeon's team to explain the risks of the proposed treatment and to obtain the patient's consent on the operating surgeon's behalf.[66] It was the evidence of the First Defendant and DW4 Dr Ivan Ng[67] that it is acceptable for an operating surgeon to rely on other members of his team to explain the surgical risks and obtain a patient's consent, notwithstanding that the patient is a private paying patient. The Plaintiff's expert PW5 Dr Tang opined that it was his practice, when he was working in the public sector, to personally obtain consent from Class B1 private paying patients and to personally explain the surgical risks to the patient. However, he acknowledged that he was not in a position to opine on the team-based care practised in public hospitals since he left for private practice in 2006.[68] Therefore, I prefer the evidence of the First Defendant.

---

64 SOC at para 40(C)(ii).

65 SOC at para 40(C)(i).

66 DW4 Dr Ivan Ng's AEIC at p 46, para 8; First Defendant's closing submissions ("D1CS") at para 18.

67 DW4 Dr Ivan Ng's AEIC at para 11.

68 9/5/19 NE 148.

Version No 1: 27 Oct 2020 (22:41 hrs)

51 This court had in *D'Conceicao Jeanie Doris (administratrix of the estate of Milakov Steven, deceased) v Tong Ming Chuan* [2011] SGHC 193 at [171] explained that to state that only a given doctor, out of the other members of a medical team, could advise on the risks of surgery "ignores the reality of how a Medical Team works in practice", and would lead to "unwanted repercussions, where each doctor has to run through all the risks of a procedure, leading to inefficiencies and an ultimately reduced quality of care". I note also that the practice of team-based care is consistent with the Singapore Medical Council's Ethical Code and Ethical Guidelines (2016 Edition) ("the 2016 ECEG"), which states as follows, at Section C6(8):

> You must either take consent personally or *if it is taken for you by a team member*, you must, through education, training and supervision of team members, ensure the quality of the consent taken on your behalf. … [emphasis added]

Although the 2016 ECEG do not apply because they post-date this case, they illustrate that the practice of team-based care, implemented in this case at NUH at least from 2014 when this case occurred, was subsequently endorsed by the medical community in 2016 through the 2016 ECEG. In any case, much the same sentiment was espoused in the 2002 edition of the ECEG (albeit in the context of treatment or care rather than specifically with regard to the taking of consent), which states at Section 4.1.1.4:[69]

> A doctor may delegate another doctor, nurse, medical student or other health care worker to provide treatment or care on his behalf, but this person must be competent to carry out the care or procedure required. …

52 Thus, quite apart from whether an operating surgeon has an obligation to personally review a patient before a surgery, which I shall address later, as

---

[69] D1CS at para 25.

Version No 1: 27 Oct 2020 (22:41 hrs)

far as obtaining consent is concerned, it is appropriate for other members of the operating surgeon's team to obtain the patient's consent and to explain the surgical risks.

(1) The Plaintiff and her family were informed of the risks of the First Surgery

53 Once this basic premise is established, whether the Plaintiff's informed consent was obtained must be seen in the light of what the other doctors she consulted at NUH (and not only the First Defendant) had told her. In this regard, the multidisciplinary progress notes ("MPNs") record that the Plaintiff was specifically informed about the risk of haemorrhage in the brain, which would include post-operative haemorrhage, as well as other risks pertaining to the First Surgery, on three separate occasions before the First Surgery:

(a) At the 15 May 2014 Consultation, DW9 Dr Ho had very comprehensively set out the risks of the First Surgery to the Plaintiff and her family. Apart from post-operative haemorrhage, this included the risks of general anaesthesia (*ie*, heart attack and stroke), infection, paralysis, permanent hearing loss, loss of facial control, diplopia (*ie*, double vision), impairment of swallowing, worsening hydrocephalus, recurrence of tumour and death.[70] The notes for the 15 May 2014 Consultation were recorded contemporaneously by DW6 Dr Ng on the same day. I emphasise that PW5 Dr Tang, the Plaintiff's own expert neurosurgeon, agreed that DW9 Dr Ho's advice regarding the risks and complications of the First Surgery was "appropriate".[71] He had opined

---

70 DBD at p 12.

71 7/5/19 NE 135.

Version No 1: 27 Oct 2020 (22:41 hrs)

that the 15 May 2014 Consultation was "a very thorough, a very comprehensive consultation, with the discussion about all the risks and the benefits of the surgery".[72] Therefore, I am unable to accept PW1 Ms Chiam's evidence that DW9 Dr Ho informed her of only the risk of facial nerve palsy.[73]

(b) At the 29 May 2014 Consultation, DW6 Dr Ng had again informed the Plaintiff and her family of the risks of the First Surgery. These risks included general anaesthesia risks (*ie*, heart attack and stroke) and surgical risks (haemorrhage, infection, paralysis, death, permanent damage to cranial nerves, numbness or shooting pain to the face, permanent hearing loss, leak of CSF and post-operative hydrocephalus). DW6 Dr Ng contemporaneously recorded the notes for the 29 May 2014 Consultation on the same day.

(c) On 1 June 2014, DW15 Dr Lu had, in the process of obtaining the Plaintiff's written consent for the First Surgery, explained the risks of the First Surgery, including haemorrhage, brainstem damage, leak of CSF, facial nervy palsy, stroke, paralysis, post-operative hydrocephalus and death. DW15 Dr Lu also explained the risk of a post-operative haematoma affecting the brainstem and that the complication rate for the First Surgery was typically 5%.[74]

54 I do not accept PW1 Ms Chiam's allegation that the MPNs are inaccurate and they contained information that was not actually communicated

---

72 7/5/19 NE 137.

73 PW1 Chiam Yu Zhu's AEIC at para 24(viii); 18/4/19 NE 125.

74 DBD at pp 12, 40 and 72.

Version No 1: 27 Oct 2020 (22:41 hrs)

to the Plaintiff and her family.[75] PW1 Ms Chiam alleges that DW9 Dr Ho had, at the 15 May 2014 Consultation, only informed the Plaintiff about the risk of facial nerve palsy.[76] Furthermore, she alleges that neither DW6 Dr Ng nor DW15 Dr Lu had informed the Plaintiff of any risks pertaining to the First Surgery, including the risk of post-operative haemorrhage, on 29 May 2014 and 1 June 2014 respectively.[77] But when PW1 Ms Chiam was asked in cross-examination why the doctors would write in things that were not said, her answer was simply that she "don't know why".[78] I cannot accept her bare denial, which flies in the face of all the contemporaneous documentary evidence recorded before the First Surgery. Further, the MPNs were separately entered by two different doctors, DW6 Dr Ng and DW15 Dr Lu, who at that time did not know this case would result in a lawsuit. There is no suggestion that the MPNs were fabricated after the event to support the Defendants' position.

55 Accordingly, I find that the Plaintiff was adequately informed of the risks of the First Surgery, which were sufficiently explained.

(2) Risk of post-operative haemorrhage

56 It is convenient to resolve here a separate issue of whether there was a higher-than-usual risk of post-operative haemorrhage in the Plaintiff's case. I accept that this is the case. The higher-than-usual risk is supported by experts

---

75 23/4/19 NE 101.

76 PW1 Chiam Yu Zhu's AEIC at para 24(viii); 18/4/19 NE 125, line 20.

77 PW1 Chiam Yu Zhu's AEIC at paras 38, 51.

78 23/4/19 NE 101.

Version No 1: 27 Oct 2020 (22:41 hrs)

from both sides. This was the opinion of DW3 Dr Hong[79] and PW3 Dr Gan,[80] while PW5 Dr Tang went so far as to say that the risk of post-operative haemorrhage is twice as high in a cystic tumour as compared to a solid tumour.[81] The First Defendant disagreed with PW5 Dr Tang.[82] The First Defendant relied on a systematic review by Dr Anil Nanda *et al* for the proposition that there were no significant differences in post-operative morbidity and mortality rates between patients with cystic VS and solid VS ("the Nanda article"). However, post-operative *morbidity and mortality* is not synonymous with post-operative haemorrhage. Thus, I am satisfied that there was a higher-than-usual risk of haemorrhage in the Plaintiff's case. But should this elevated risk have been specifically conveyed to her, above and beyond the risk of haemorrhage *per se*? Her family had, after all, been informed before the First Surgery that haemorrhage could be one of the possible consequences. The doctors would have considered that the risk of haemorrhage was one that was relevant and material, having regard to factors such as the likelihood of the risk and the consequences if it actuated (*Hii Chii Kok* at [40]). It was not as if the risk of haemorrhage was ignored altogether. What was told to the Plaintiff and her family would be adequate for the purposes of seeking informed consent. The Plaintiff's tumour was very large and all the neurosurgeons whom the Plaintiff went to seek various expert opinions, came to the same conclusion that it had to be removed surgically. She would have died otherwise. I accept the First

---

79 8/7/19 NE 99.

80 25/4/19 NE 8-11.

81 10/5/19 NE 140-141.

82 15/5/19 NE 53-54; 22/5/19 NE 49-50.

Version No 1: 27 Oct 2020 (22:41 hrs)

Defendant's argument that the Plaintiff has not shown that the elevated risk of haemorrhage, specifically, was relevant and material for her to know.[83]

Strategy for managing post-operative haemorrhage

57 I do not accept that the First Defendant was required to explain to the Plaintiff his *strategy* for managing post-operative haemorrhage as opposed to the *risk* of haemorrhage. Regarding the latter, the evidence shows that the Plaintiff and her children who accompanied her were told, on three separate occasions, that post-operative haemorrhage was a known risk of the First Surgery.

58 The Plaintiff identified the "strategy" for dealing with post-operative haemorrhage as "careful and vigilant monitoring of her condition by [the First and Second Defendant] at acceptable intervals so that appropriate and timely intervention [can] be carried out".[84] But this need not be communicated to the Plaintiff because it is *to be expected* that a patient who has undergone brain surgery must be monitored closely. Whether or not such monitoring is negligent in the Plaintiff's case is a separate matter altogether. Furthermore, the First Defendant's approach to intervention if there were post-operative haemorrhage would turn on numerous factors, including the site of the haemorrhage, the size of any haematoma and the prognosis of the patient. That would, therefore, be speculative at the point of obtaining informed consent for the First Surgery. In this regard, the Court of Appeal's caution in *Hii Chii Kok* at [143] bears emphasising:

---

83 D1CS at para 82a.

84 SOC at para 40(B)(ii).

Version No 1: 27 Oct 2020 (22:41 hrs)

> … The reasonable patient would not need or want to know and understand every iota of information before deciding on whether to undergo the proposed treatment. Indeed, it has been observed that *indiscriminately bombarding the patient with information, in what has been colourfully described as an 'information dump', tends to have the* ***opposite effect of leaving the patient more confused and less able to make a proper decision****. …* [emphasis added in italics and bold italics]

Identity of the surgeon who would perform the First Surgery

59 I accept that the identity of the surgeon who would perform the First Surgery was relevant and material for the Plaintiff, as the First Defendant rightly conceded.[85] PW5 Dr Tang testified that patients have the right to know who is to perform the surgery. Citing the 2016 ECEG at Section C6(4), the more invasive the surgery the more "specific and detailed must be the information about the persons conducting it".[86]

60 The parties agree that on 1 June 2014, the night before the First Surgery, the Plaintiff and her family were informed by DW15 Dr Lu that the First Defendant would be the operating surgeon for the First Surgery. PW1 Ms Chiam alleges that the Plaintiff and her family did not have sufficient time to react when they were informed by DW15 Dr Lu that the First Defendant would be the operating surgeon.[87] Had they been informed earlier, the Plaintiff and her family would have objected to the First Defendant being the operating surgeon and would have chosen DW9 Dr Ho or Dr Lee from Gleneagles Hospital instead.

---

85 D1CS at para 39.

86 7/5/19 NE 194; 9/5/19 NE 145.

87 24/5/19 NE 26.

Version No 1: 27 Oct 2020 (22:41 hrs)

61 Since PW1 Ms Chiam alleges that this was the first time the Plaintiff and her family were informed that the First Defendant would be performing the First Surgery,[88] the issue is whether they were told before this (*ie*, at the 15 May 2014 Consultation or the 29 May 2014 Consultation) that the First Defendant, and not DW9 Dr Ho, would be the surgeon. I shall now review what happened at the preceding Consultations.

(1) The 15 May 2014 Consultation

62 PW1 Ms Chiam alleges that the Plaintiff and her family were told by DW9 Dr Ho at the 15 May 2014 Consultation that he could be chosen as the operating surgeon for the First Surgery scheduled on 2 June 2014, if the Plaintiff was upgraded to a private paying patient in Class B1.[89] Subsequently, the Plaintiff's family proceeded to make the necessary arrangements for the upgrade. The Plaintiff further alleges that the admission financial counselling form listed DW9 Dr Ho under "Admitting Ward/Bed".[90] The Plaintiff was also given an appointment card for a follow-up consultation with DW9 Dr Ho on 29 May 2014.[91]

63 I find that DW9 Dr Ho had not, at the 15 May 2014 Consultation, told the Plaintiff that he would be the surgeon, for the following reasons.[92]

---

88 PW1 Chiam Yu Zhu's AEIC at para 46; 23/4/19 NE 131.

89 18/4/19 NE 82 line 23; CYZ-1 at para 26.

90 DBD at pp 47–48.

91 Plaintiff's Bundle of Documents ("PBD") at p 8.

92 DW9 Dr Ho's AEIC at p 27.

Version No 1: 27 Oct 2020 (22:41 hrs)

64 Firstly, DW9 Dr Ho explained that he had on 22 April 2014 (prior to the 15 May 2014 Consultation) already made arrangements to undergo cataract surgeries on 26 May 2014 and 29 May 2014 for both his eyes. He went for his scheduled cataract surgeries on those dates. This was supported by a letter written from DW9 Dr Ho's eye surgeon.[93] Therefore, he would have been on medical leave and it would not have been possible for him to conduct such a serious and major surgery on 2 June 2014. I do not accept that DW9 Dr Ho was so remiss that his own cataract surgeries slipped his mind.

65 Secondly, DW9 Dr Ho *could not* have confirmed on the spot at the 15 May 2014 Consultation that he would be the operating surgeon as he was only a visiting consultant who would have to seek the First Defendant's approval to perform any surgery at NUH.[94]

66 Thirdly, I do not accept the Plaintiff's contention that DW9 Dr Ho had told them he would be the surgeon if they upgraded to Class B1. DW9 Dr Ho testified that he was not entitled to take an existing private paying patient from NUH to operate and earn from that surgery. He was only entitled to operate on subsidised patients because of the nature of his clinic.[95]

67 Fourthly, the relevant documents executed by the Plaintiff on 15 May 2014 would not have given the Plaintiff the impression that DW9 Dr Ho was to be the surgeon. It is true that the Plaintiff did sign an admission financial counselling form on 15 May 2014 with DW9 Dr Ho's name listed under "Admitting Ward/Bed". DW6 Dr Ng explained that he had written DW9

---

93 DW9 Dr Ho's AEIC at p 27.

94 16/7/19 NE 128-129.

95 6/7/19 NE 163-164.

Version No 1: 27 Oct 2020 (22:41 hrs)

Dr Ho's name because it was necessary to indicate a consultant's name to admit a patient and DW9 Dr Ho was the only consultant neurosurgeon who had met the Plaintiff at the material time.[96] However, that form must be viewed together with a *subsequent* admission financial counselling form, signed by PW1 Ms Chiam at the 29 May 2014 Consultation, which clearly listed the First Defendant under "Admitting Ward/Bed".[97] For completeness, I note there was another pre-admission form dated 15 May 2014 that lists the surgeon as "Ho Kee Hang", with DW6 Dr Ng's name cancelled out.[98] But DW6 Dr Ng explained that this form was for the hospital's internal use and would never have been shown to the Plaintiff or her family.[99] Therefore, this latter form *could not* have affected the deliberation of the Plaintiff's family.

68 Accordingly, I find that DW9 Dr Ho had not told the Plaintiff that he would operate on her at the 15 May 2014 Consultation. Three doctors (*ie*, DW15 Dr Lu, DW6 Dr Ng and DW9 Dr Ho) who attended to the Plaintiff at the 15 May 2014 Consultation had categorically and definitively testified that DW9 Dr Ho would not be the Plaintiff's surgeon. I have no reason to disbelieve these doctors. Against this, PW1 Ms Chiam vehemently asserted that DW9 Dr Ho would be the Plaintiff's surgeon. There is no evidence for her belief, and I can only attribute this to some unfortunate misunderstanding between the doctors and the Plaintiff's family. Perhaps, the Plaintiff and her family had jumped to the conclusion that DW9 Dr Ho would be the surgeon without seeking confirmation from him, based on the fact that he had booked the operating

---

96 DW6 Dr Ng Zhi Xu's AEIC at para 15; 12/7/19 NE 84.

97 DBD at p 49.

98 DW6 Dr Ng Zhi Xu's AEIC at p 12.

99 12/7/19 NE 82.

Version No 1: 27 Oct 2020 (22:41 hrs)

theatre on 2 June 2014 and they were told to return to DW9 Dr Ho's clinic on 29 May 2014. This is illustrated by PW1 Ms Chiam's response in cross-examination:[100]

> MR TOH: Ms Chiam, you said on 26 May 2014 it was captured in the WhatsApp group that Dr Ho said he would be the operating surgeon if Mdm Goh upgraded to be a private patient. Could you let us know which message you are referring to?
>
> A: Your Honour, I have to correct my earlier statement that he confused me by the date. Just now I was referring also to date on 24 May, Dr Ho quickly suggest -- just now I was being confused by the way he posed my question. So just now I already mentioned on page 27, Dr Ho already mentioned, quickly make a suggestion, this is what he told -- I earlier mentioned, but I was got confused by the date that he provide me just now. So I -- my stand is still the same. On 24 May, Dr Ho quickly made the suggestion.
>
> Q: Ms Chiam, the suggestion was to book an OT on 2 June 2014 for no more delay. It is not stated here that Dr Ho said that he would be the operating surgeon if Mdm Goh upgraded to be a private patient. Do you agree?
>
> A: Your Honour, in this statement he -- this question he ask me, there's two questions that I see. He's asking me, suggest was to book for OT on 2 June for no more delay. I agree with this part. Will he be operating surgeon? *My understanding is he is the one who told us that he going to book for operating theatre, it wasn't -- it will be him to be the one; right?* Sorry, I interpret.
>
> (Through interpreter) *If he never said that he would be the operating surgeon, why would he wanted us to go and book the operating theatre?* And we already said that we would be upgrading my mum because we wanted to choose the doctor.
>
> [emphasis added]

---

100 23/4/19 NE 40/19–41/25.

Version No 1: 27 Oct 2020 (22:41 hrs)

(2) The 29 May 2014 Consultation

69 The Plaintiff's contention is that she was only informed on 1 June 2014 that the First Defendant would be the surgeon operating on the Plaintiff. This was against the evidence that clearly shows that at the 15 May 2014 Consultation the Plaintiff and her family were told that DW9 Dr Ho would not be the operating surgeon. Furthermore, at the 29 May 2014 Consultation the Plaintiff and her family were informed that the First Defendant would be the surgeon.

70 The contemporaneous documents support DW6 Dr Ng's evidence that he had informed the Plaintiff and her family at the 29 May 2014 Consultation that the First Defendant would be performing the First Surgery. DW6 Dr Ng recorded in the MPN for the 29 May 2014 Consultation that the First Defendant was "agreeable to assist in [the Plaintiff's] surgery on behalf of [DW9 Dr Ho]".[101]

71 Furthermore, PW1 Ms Chiam testified that the Plaintiff and her family "were very careful about who [they] wanted to perform the surgery".[102] This is consistent with the conduct of PW1 Ms Chiam and her siblings in seeking several opinions from other neurosurgeons for the best interests of the Plaintiff before the First Surgery. The WhatsApp messages disclosed by the Plaintiff also revealed that the identity of the operating surgeon was of significant importance to her and her siblings. Given that the First Surgery was four days away, it was logical that the Plaintiff and her family would have discussed with DW6 Dr Ng who the operating surgeon would be.

---

101 DBD at p 12.

102 18/4/19 NE 21.

Version No 1: 27 Oct 2020 (22:41 hrs)

72 DW6 Dr Ng further explained that during the 29 May 2014 Consultation, the Plaintiff's family had requested someone senior to perform the First Surgery and that they did not mind paying private class fees, if necessary. The Plaintiff's family had also enquired about the seniority of the First Defendant, to which DW6 Dr Ng replied that he was the Head of the Division of Neurosurgery.[103] The fact that the First Defendant was the Head of the Division of Neurosurgery must have satisfied and re-assured the Plaintiff and her family that she was in good and capable hands. DW6 Dr Ng's account is consistent with the documents which show that the Plaintiff was only upgraded to a private paying patient under Class B1 on 29 May 2014 and not on 15 May 2014 as PW1 Ms Chiam had contended. The surgeon who was indicated on the admission financial counselling form recorded on 29 May 2014 was the First Defendant and not DW9 Dr Ho.[104] In contrast, the admission financial counselling form recorded on 15 May 2014 stated that the Plaintiff was a subsidised patient under Class B2.[105] That form clearly states that Class B2 patients are not entitled to choose their doctor.[106]

73 Therefore, even if the Plaintiff and her family had mistakenly believed that DW9 Dr Ho would be the surgeon operating on the Plaintiff at the 15 May 2014 Consultation, they would have become aware by the 29 May 2014 Consultation that the First Defendant would be the operating surgeon for the First Surgery. They accepted this knowing that the Plaintiff was in good hands. It would not be beyond the Plaintiff's family to search on the Internet the

---

103 DW6 Dr Ng Zhu Xu's AEIC at para 24.

104 DBD at p 49.

105 PBD at p 4.

106 PBD at p 5.

Version No 1: 27 Oct 2020 (22:41 hrs)

background and track records of the First Defendant to evaluate his competence and skill as a neurosurgeon – in fact, they had done so in respect of Dr Lee and Dr Khoo when seeking other opinions on the Plaintiff's medical condition. Therefore, I am unable to accept PW1 Ms Chiam's contention that the Plaintiff was only told that the First Defendant would be the operating surgeon on 1 June 2014. For the same reasons, I find it difficult to accept PW1 Ms Chiam's assertion that the Plaintiff and her family would have chosen to seek treatment under Dr Lee if the First Defendant had informed the Plaintiff before 1 June 2014 that he would be the operating surgeon. The contemporaneous evidence is consistent with the Defendants' case that the Plaintiff and her family were, on 29 May 2014, keen for the First Defendant to perform the First Surgery.

74 Separately, regarding the identity of the operating surgeon, the First Defendant contends that an adverse inference should be drawn against the Plaintiff for not disclosing the relevant WhatsApp messages which would show that the Plaintiff was informed on 29 May 2014 that the First Defendant would be the operating surgeon.[107] I am of the view that there is sufficient evidence to support my findings on this issue without having to draw an adverse inference. However, I find that PW1 Ms Chiam has been less than forthcoming with the WhatsApp messages. She refused to disclose the WhatsApp messages, claiming initially that the reason for ignoring the First Defendant's request for disclosure was that "it's a personal chat".[108] Later in her cross-examination she gave various other explanations including that her handphone had broken down,[109] that a new WhatsApp group was created and that her sisters had also changed

---

107 D1CS at para 61.

108 23/4/19 NE 48.

109 23/4/19 NE 55.

Version No 1: 27 Oct 2020 (22:41 hrs)

to new handphones.[110] When confronted about how she could have offered to produce a photograph of the Plaintiff in diapers she claimed that it was in the family group chat, PW1 Ms Chiam vacillated and said that "the photo were definitely in the photo … album but the chat doesn't -- don't have in the album what [*sic*]".[111] PW1 Ms Chiam's explanations bordered at times on the incredible, all of which undermines her credibility.

The First Defendant's availability after the Second Surgery

75 Given the team-based care practiced at NUH, it was not necessary for the First Defendant to have informed the Plaintiff of his availability in particular after the Second Surgery.

76 Generally, in a public hospital which practises team-based care, it is appropriate for a doctor to hand over the post-management care of a patient to other members of his team. However, the doctor retains overall responsibility for the patient and must take reasonable care to ensure that the other doctors are capable of providing care to the required quality and standards (2016 ECEG at Section A4(1)). Seen in this light, the fact that the First Defendant would be on leave from 4 June 2014 was not something that needed to be disclosed to the Plaintiff and her family before the First Surgery. Furthermore, the First Defendant did not foresee before the surgery that the Plaintiff's condition would take a catastrophic turn for the worse four hours after an uneventful and successful operation. Moreover, his leave only started two days after the First Surgery and he cannot be faulted for believing that the Plaintiff would be well looked after by his team under the system of team-based care. The First

110 23/4/19 NE 56.

111 23/4/19 NE 55.

Version No 1: 27 Oct 2020 (22:41 hrs)

Defendant ensured that the Plaintiff was well looked after when he was on leave. He informed the Plaintiff's family that Dr Sein Lwin, a consultant, and Assoc Prof Chou Ning would care for her. The First Defendant had also apprised Dr Sein Lwin of the Plaintiff's condition in detail and the future management.

77 The Plaintiff has not shown, prior to the surgery, that it was relevant and material to her that the First Defendant would be going on leave soon after the First Surgery. She did not indicate at any point during the consultations on 15 May 2014, 29 May 2014 and 1 June 2014 that she would *only* consent to undergoing the First Surgery if the operating surgeon would be present to provide post-operative care on the days after the First Surgery.

Causation for pre-operative stage

78 Hence, there was no failure in securing the Plaintiff's informed consent before the First Surgery. Even if there had been, causation would not be made out. It is undisputed that surgery to remove the tumour was necessary – in fact it was the only option – for the Plaintiff to survive. The Plaintiff has not proven, on a balance of probabilities, that she would not have proceeded with the First Surgery under the First Defendant if the information she alleges was relevant and material was disclosed. This has to be assessed against the time and financial constraints she and her family faced. In any case, the Plaintiff has not alleged that the First Defendant was negligent in carrying out the First Surgery and that this led to her PVS. It is undisputed that the First Surgery was successfully carried out. Seen in that light, it would not have made a difference if the First Surgery had been carried out by the First Defendant or someone else such as DW9 Dr Ho or Dr Lee. Thus, the Plaintiff would have failed on causation regarding the allegations of pre-operative negligence.

Version No 1: 27 Oct 2020 (22:41 hrs)

Whether the First Defendant should have personally reviewed the Plaintiff before the date of the First Surgery

79 It is not disputed that the First Defendant saw the Plaintiff at the operating theatre for the first time on the day of the First Surgery, *ie*, 2 June 2014.[112] According to the First Defendant, he examined the Plaintiff that morning and spoke to her about the nature of the proposed surgery and the attendant risks.[113] He stated that it was his usual practice to examine a patient before the surgery and to explain the surgical risks.[114] This practice is borne out as he had instructed a nurse to arrange for a consultation with the Plaintiff on 27 May 2014, which the Plaintiff and her daughters, unfortunately, had chosen not to attend.

80 The Plaintiff's complaint is that the First Defendant was negligent because he failed to personally examine and review her *before* the day of the First Surgery.

81 In my view, this issue cannot be divorced from the preceding issue of whether the Plaintiff had received adequate explanation of the risks of the First Surgery and given informed consent of the same. I find that the First Defendant was not negligent simply because he did not personally examine and review the Plaintiff before the day of the First Surgery, for the reasons given below.

82 Firstly, the Plaintiff was adequately advised about the nature of the First Surgery and its accompanying risks by the Second Defendant's team of

---

112 ASOF at S/N 11.

113 Dr Yeo's AEIC at para 36.

114 Dr Yeo's AEIC at para 33.

Version No 1: 27 Oct 2020 (22:41 hrs)

neurological surgeons and doctors at the 15 May 2014 Consultation, 29 May 2014 Consultation and on 1 June 2014. On these three separate occasions, the Plaintiff's condition was correctly and comprehensively assessed by the respective doctors.

83 Secondly, the First Defendant was familiar with the details of the Plaintiff's case. Her clinical history was properly documented in the MPNs and the First Defendant had reviewed these notes before the First Surgery.[115] The First Defendant was also apprised of the Plaintiff's case through the Department Meeting on 22 May 2014. The Plaintiff has not explained what the alleged shortcomings were, arising from the lack of personal review before the day of the First Surgery, that would have made a difference to (for instance) what the First Defendant would have done regarding the Plaintiff's diagnosis and treatment.

84 Thirdly, the First Defendant's failure to personally see the Plaintiff before the day of the First Surgery must be seen in the light of the Plaintiff's failure to turn up for her scheduled consultation with the First Defendant on 27 May 2014. ***As a matter of good clinical practice and courtesy***, the First Defendant ought perhaps to have personally met and reviewed the Plaintiff in the presence of her family members *before* the First Surgery. When he realised that the Plaintiff had decided to go ahead with the surgery on 2 June 2014 at NUH and this was an elective surgery with significant risks including death, he ought to have at least met the Plaintiff and her family before the patient was sent to the operating theatre for the First Surgery. In this regard, I would like to refer

115 Dr Yeo's AEIC at para 33.

Version No 1: 27 Oct 2020 (22:41 hrs)

to the opinion of DW4 Dr Ivan Ng, the First Defendant's own expert neurosurgeon:[116]

> While the consultant in charge is not required to take consent personally, it is my opinion that the operating neurosurgeon should personally examine, review and obtain consent especially for an elective operation. *This is important from a clinical practice standpoint so that we can establish a patient-doctor relationship.* Whilst it may be sometimes impossible in a public hospital to personally speak with [the] patient and family before the operation due to urgency and constraints of time in an emergency procedure, *it should not be an issue in a purely elective operation.* [emphasis added]

This would have been a good clinical practice, and it is heartening to note that the First Defendant said that he always makes it a point to review and meet his patient before the surgery. However, the apparent shortcoming of doctor-patient courtesy arising from the unusual circumstances of this case, in my view, does not amount to negligence.

85 This was an unfortunate situation where the Plaintiff did not turn up on 27 May 2014 for the scheduled consultation with the First Defendant and the First Defendant was subsequently occupied with a conference in Bangkok until just before the First Surgery on 2 June 2014. The First Defendant was scheduled to meet the Plaintiff on 27 May 2014. *The Plaintiff's family decided not to bring the Plaintiff for this consultation* as they had mistakenly believed that DW9 Dr Ho was the operating surgeon. But even if the Plaintiff and her family had thought that DW9 Dr Ho was to be the surgeon they should have, nevertheless, turned up for the appointment, especially when NUH had called PW1 Ms Chiam and later spoken to Carol on 26 May 2014 to inform the family to bring the Plaintiff to see the First Defendant. They should have accorded importance and

---

116 DW4 Dr Ivan Ng's AEIC at para 11.

Version No 1: 27 Oct 2020 (22:41 hrs)

urgency to the call from the Second Defendant's staff because the First Surgery was imminent. Furthermore, the Plaintiff was unwell to the extent that it was necessary for her family to send her to the A&E department at NUH on the same day as the telephone call, *ie*, 26 May 2014. Anyone in these circumstances would have been worried that there were urgent or serious developments regarding the Plaintiff's condition, as NUH wanted the Plaintiff to see the First Defendant on 27 May 2014. Instead, PW1 Ms Chiam and her family unilaterally decided not to bring the Plaintiff to NUH on 27 May 2014. In my view, it was wrong of the Plaintiff and PW1 Ms Chiam to have completely ignored this consultation on 27 May 2014 even though they might have the mistaken belief that DW9 Dr Ho was the Plaintiff's surgeon. If the Plaintiff had turned up on 27 May 2014, she and her family would have known that the First Defendant would be the Plaintiff's surgeon and any misunderstanding about DW9 Dr Ho being the Plaintiff's surgeon would have been cleared up. I attribute this failure to keep the consultation on 27 May 2014 as a serious negligence on the part of the Plaintiff and PW1 Ms Chiam. The latter cannot now turn around and accuse the First Defendant for being negligent as he had not seen the Plaintiff personally before 2 June 2014.

86 Accordingly, the fact that the First Defendant only personally reviewed the Plaintiff on the morning of the First Surgery does not amount to any inadequacy or breach of patient care or negligence on the part of either of the Defendants. Nor has the Plaintiff explained how the First Defendant's approach towards her treatment would or could have differed if he had reviewed her personally before the date of the First Surgery.

Version No 1: 27 Oct 2020 (22:41 hrs)

Conclusion on negligence alleged at the pre-operative stage

87 To summarise, the First Defendant was not negligent at the pre-operative stage. Firstly, I find that the Plaintiff's informed consent was obtained for the First Surgery. While the Plaintiff alleges that the risks of the First Surgery were not communicated to her, apart from facial nerve palsy, this is flatly contradicted by the contemporaneous documents entered by two different doctors. The entries in these documents show that on three separate occasions, the risks of the First Surgery, including haemorrhage in the brain, were communicated to the Plaintiff and her family. I reiterate that the Plaintiff's own expert witness, PW5 Dr Tang, agreed that the advice given by the various doctors to the Plaintiff and her family regarding the risks of the First Surgery was correct and comprehensive.[117] I also accept that in a public hospital that practises team-based care, it is reasonable for other members of the operating surgeon's team to explain the risks of the proposed treatment and to obtain the patient's consent on the operating surgeon's behalf.

88 The Plaintiff also alleges that the First Defendant should have informed her about his strategy for managing post-operative haemorrhage. No expert evidence or guidelines were adduced to show why such information must be explained to the patient before consent for surgery is sought from the patient. Such information would also be speculative as it would depend on various factors, including the site of the haemorrhage, the size of any haematoma and the patient's prognosis. This speculative deluge would have overwhelmed and confused the Plaintiff and her family.

---

117 7/5/19 NE 135 line 23.

Version No 1: 27 Oct 2020 (22:41 hrs)

89 In addition, I also do not accept the Plaintiff's contention that the First Defendant should have advised her that he would be on leave two days after the First Surgery. This is not information that would have been relevant and material, particularly when the Second Defendant practised team-based patient care. Furthermore, the First Defendant's leave only started two days after the First Surgery. It was appropriate for the First Defendant to hand over post-management care to other members of his team. The First Defendant had retained overall responsibility for the Plaintiff and taken reasonable care to ensure that the other members of his team were capable of providing the requisite care.

90 The Plaintiff contends that she was only informed one day before the First Surgery that the First Defendant would be the operating surgeon. In the circumstances, there was insufficient time for them to react. If this was communicated to the Plaintiff and her family members earlier, the Plaintiff would have sought treatment under DW9 Dr Ho or Dr Lee instead. However, I find that the evidence is clear that the Plaintiff and her family members were, in fact, told during the 29 May 2014 Consultation that the First Defendant would be the operating surgeon for the First Surgery. Thus, there was sufficient time for the Plaintiff to back out of the First Surgery, an elective surgery, if she did not wish to proceed.

91 Secondly, the First Defendant was not negligent in failing to personally review the Plaintiff before the date of the First Surgery, 2 June 2014. He was well apprised of the Plaintiff's case through the Department Meeting on 22 May 2014. He had also examined the RadLink MRI. While he did not personally review the Plaintiff before 2 June 2014, the three doctors who attended to her on three separate occasions *ie*, DW9 Dr Ho, DW6 Dr Ng and DW15 Dr Lu, had: (i) advised her about the nature and risks of the First Surgery, (ii) adequately

Version No 1: 27 Oct 2020 (22:41 hrs)

assessed her condition, and (iii) documented her clinical history. The First Defendant had reviewed the clinical notes of the three consultations before the First Surgery.

92 As a matter of good clinical practice, the First Defendant ought, perhaps, to have personally reviewed the Plaintiff before the First Surgery. However, this has to be balanced against the unique circumstances in this case. The Plaintiff was originally scheduled to meet the First Defendant on 27 May 2014 but did not turn up for the consultation. In addition, the First Defendant had to attend a conference in Bangkok very shortly thereafter and only returned the day before the First Surgery. In the light of these circumstances, I find that there was no negligence on the part of the First Defendant in failing to personally review the Plaintiff before 2 June 2014.

93 It follows from my finding that the First Defendant was not negligent at the pre-operative stage that the Second Defendant cannot be vicariously liable for negligence. Considering the strength of the evidence supporting this conclusion, it was unsurprising that the Plaintiff decided, belatedly, at the close of the trial not to pursue her claim of negligence against the Defendants at the pre-operative stage.

Post-operative stage

94 The Plaintiff concentrates her action against the Defendants for acts of negligence at the post-operative stage and the following are the issues:

(a) failing to adequately monitor and care for the Plaintiff after the First Surgery;

Version No 1: 27 Oct 2020 (22:41 hrs)

(b) misreading the First CT Scan and diagnosing a significant intra-axial haematoma;

(c) failing to evacuate the haematoma; and

(d) failing to advise the Plaintiff's family of the option to evacuate the haematoma.

95 Before I deal with the above issues in *seriatim*, I shall first address the Plaintiff's arguments that factual witnesses who are neurosurgeons cannot give expert opinions on issues concerning medical practice. The Plaintiff further urges that such expert views must be rejected or given little weight because these factual witnesses have not complied with O 40A of the Rules of Court (Cap 322, R 5, 2014 Rev Ed) ("Rules of Court").[118]

Can medical factual witnesses give expert opinions on medical practice that are within their domain of proficiency?

96 The factual witnesses that the Plaintiff objects to their giving of expert views are, primarily, the First Defendant and DW11 Dr Pang.[119] The Defendants were content to withdraw the relevant portion of DW9 Dr Ho's affidavit that was opinion evidence.[120]

97 It is indisputable that as a matter of general principle, only expert witnesses may give opinion evidence. However, that proposition must be applied sensibly. That principle applies in full force where *lay* factual witnesses

---

118 PCS at para 37.

119 PCS at paras 296, 154, 38.

120 16/7/19 NE 107.

Version No 1: 27 Oct 2020 (22:41 hrs)

purport to give expert opinion. For instance, in *Longyuan-Arrk (Macao) Pte Ltd v Show and Tell Productions Pte Ltd and another suit* [2013] SGHC 160, a case cited by the Plaintiff, a production manager deposed that he had personally supervised the replacement of certain signs and that all of them were rusty. He added that if the signs were hot-dip galvanised, "there would be shine". The court disallowed the latter addition as he was called as a factual witness and it was too late in the day to have him take the stand as an expert witness. Further, proper information on his credentials to qualify him as an expert was not available (at [93]). That was also the conclusion in two other cases cited by the Plaintiff. In *Goh Yeow Hwee v Tan Buck Chye* [2008] SGDC 378 (at [28]) there was insufficient evidence on the credentials of a party who was to have given evidence by way of a statement on the authenticity of the painting. In *JU and another v See Tho Kai Yin* [2005] 4 SLR(R) 96 (at [54]) the court found that the individual concerned – who was initially put forth as a factual witness and later purportedly as an expert – was not even qualified to be an expert. The rationale where *lay* witnesses are concerned is that allowing lay witnesses to give opinion evidence would offend the general rule that inferences and interpretation of facts must be made by the court and not the witness (*Sim Cheng Soon v BT Engineering Pte Ltd and another* [2007] 1 SLR(R) 148 at [22]).

98 This general principle should not be applied blithely. There may be instances in which to exclude the evidence of factual witnesses who possess expert knowledge that is directly relevant to the issues in the trial may not be justified. In this case, I refer to the First Defendant and DW11 Dr Pang who are experienced and accomplished neurosurgeons.

(a) The First Defendant's credentials are not to be downplayed. In his affidavit, he is stated to be "a Senior Consultant and the Head of the Division of Neurosurgery in the Department of Surgery at the 2nd

Version No 1: 27 Oct 2020 (22:41 hrs)

Defendant's hospital, the National University Hospital". He is also "the Medical Director of the Singapore Gamma Knife Centre since 1997", and "an Clinical Associate Professor with the Yong Loo Lin School of Medicine, National University of Singapore." The First Defendant obtained his specialist qualification in neurosurgery from the Royal Australasian College of Surgeons in Melbourne. Thereafter, he "underwent further subspecialty training in stereotactic and functional neurosurgery in Canada, the United States of America and France".

(b) DW11 Dr Pang also has wide experience and knowledge about neurosurgery that is relevant to this case. When DW11 Dr Pang was asked by the Plaintiff's counsel as to how many brain surgeries he had done since 2 June 2014, he estimated about 150 to 200 per year.[121] DW11 Dr Pang is a senior consultant at the Department of General Surgery of Khoo Teck Puat Hospital and he is also a visiting senior consultant neurosurgeon at the Ng Teng Fong General Hospital. In 2004 he underwent neurosurgery training at the Royal Australasian College of Surgeons' neurosurgical training programme. He also had undergone neurosurgical training at the National Neuroscience Institute, Singapore and the Princess Alexandra Hospital, Brisbane, Australia. In 2009 he was awarded a Fellowship in Neurosurgery from the Royal Australasian College of Surgeons. From 2009 to 2013 he served as co-director of the Neuro Intensive Care at Tan Tock Seng Hospital. He is also a clinical lecturer for General Surgery at the Yong Loo Lin School of Medicine, National University of Singapore.

---

121 18/7/19 NE 68.

Version No 1: 27 Oct 2020 (22:41 hrs)

99 It would be a miscarriage of justice if the First Defendant were, for instance, barred from explaining in his defence on how he came to arrive at his venous infarct theory, or from recounting his experience of whether a person's pons would rebound post-surgery (these being some issues that I shall discuss in much greater detail below). Where such issues are critical to the defence and the medical opinions are as important as the factual matters, the medical opinions (albeit expressed by factual witnesses) form an integral part of the defence. To disallow the First Defendant to rely on his medical expertise in his defence will be unfairly prejudicial. As the First Defendant's counsel pointed out,[122] relying on *Attorney-General v Au Wai Pang* [2015] 2 SLR 352 at [48], in the first place, the fact that a person has a particular opinion may be admissible if it is relevant, as when it is adduced to explain his conduct. Moreover, defendant medical practitioners have routinely been allowed to explain their thoughts, theories, and rationales for their actions at the material time as part of their defence (see *eg*, *Khoo James and another v Gunapathy d/o Muniandy and another appeal* [2002] 1 SLR(R) 1024 ("*Khoo James*") at [41]). The views expressed in *DN (by his father and litigation friend RN) v London Borough of Greenwich* [2004] EWCA Civ 1659 are also worth bearing in mind. That case involved a defendant psychologist who was sued by one of his patients for negligently preparing a report that led to him receiving education that was not suited to his needs. The defendant did not call any experts and relied only upon his own testimony. The English Court of Appeal stated (at [25]–[26]):

> 25. It very often happens in professional negligence cases that a defendant will give evidence to a judge which constitutes the reason why he considers that his conduct did not fall below the standard of care reasonably to be expected of him. He may do this by reference to the professional literature that was reasonably available to him as a busy practitioner or by

---

122 First Defendant's reply submissions ("D1RS") at paras 6–8.

Version No 1: 27 Oct 2020 (22:41 hrs)

> reference to the reasonable limits of his professional experience; or he may seek to rebut, as one professional man against another, the criticisms made of him by the claimant's expert(s). Such evidence is common, and it is certainly admissible. …
>
> 26. Of course a defendant's evidence on matters of this kind may lack the objectivity to be accorded to the evidence of an independent expert, but this consideration goes to the cogency of the evidence not to its admissibility. …

I find these views to be persuasive and a complete answer to the Plaintiff's objections to the First Defendant's reliance on his own medical opinions and experience, or case studies that he produced as exhibits during trial.[123]

100 I now deal with the Plaintiff's argument on O 40A of the Rules of Court. She contends that this provision sets out the procedure for expert witnesses to comply with. The factual witnesses, namely the First Defendant and DW11 Dr Pang, did not comply with these provisions. Thus, their medical opinions are inadmissible. Order 40A is clearly meant to prescribe the evidence of witnesses that are called solely for the purpose of providing expert opinions on the issues before the court. The provisions in O 40A are not meant for factual witnesses who have expert knowledge relevant to the issues before the court. It is incorrect for the Plaintiff to argue that a failure to comply with O 40A means that the expert opinions are inadmissible. Order 40A does not define whether a witness is an expert on a particular subject matter. It is the court that decides whether a witness qualifies as an expert (see *Singapore Civil Procedure 2019* vol I (Chua Lee Ming gen ed) (Sweet & Maxwell, 9th Ed, 2019) ("*Singapore Civil Procedure*") at para 40A/1/2):

> … If the court is satisfied that the witness has sufficient knowledge or expertise to qualify as an expert, he could be regarded as such. In *Commercial Union Assurance Co. plc v. Lee*

---

123 1D12.

Version No 1: 27 Oct 2020 (22:41 hrs)

> *Siew Khuan* [1991] 2 M.L.J. 541, the court felt entitled to rely on the evidence of an advocate and solicitor on the estimated value of a missing diamond ring as he was shown to know enough about diamonds to assess their value. The court does not need to insist that the expert witness must be professionally qualified. The ability to give expert evidence may be justified by his experience concerning the matters in question but the experience must relate specifically to those matters and the fact that he has not acquired his knowledge professionally goes to weight and not to admissibility: *Kong Nan Siew v. Lim Siew Hong* [1971] 1 M.L.J. 262. … [emphasis added]

101 Therefore, certain factual witnesses who have the required experience and medical knowledge about neurosurgery have relevant evidence to give, and can express their opinions notwithstanding that O 40A may not have been complied with. The expert opinions of the factual witnesses in this case must be determined and considered together with the other expert opinions before appropriate weightage is given.

The law on medical negligence

102 The applicable law, which is derived from *Bolam v Friern Hospital Management Committee* [1957] 1 WLR 582 ("*Bolam*") and *Bolitho v City and Hackney Health Authority* [1998] AC 232 ("*Bolitho*") is not in doubt. The *Bolam* test with the *Bolitho* addendum ("the *Bolam-Bolitho* test") applies in assessing whether the Defendants were negligent: *Hii Chii Kok* at [76]. Because of the significance of the *Bolam-Bolitho* test to my analysis, it is useful to outline these principles in greater detail.

103 The *Bolam* test considers whether the defendant doctor's practice is supported by a responsible body of opinion within the profession, even if there is another body of opinion which disagrees. As stated in *Bolam* at 587:

> … [A doctor] is not guilty of negligence if he has acted in accordance with a practice accepted as proper by a responsible body of medical men skilled in that particular art. … Putting it

Version No 1: 27 Oct 2020 (22:41 hrs)

> the other way round, a man is not negligent, if he is acting in accordance with such a practice, merely because there is a body of opinion who would take a contrary view. …

The rationale for the *Bolam* test is that a court should not arrogate to itself the function of resolving a genuine controversy that even medical experts cannot agree. It would be unfair to penalise a defendant for holding a view that other members in his profession reasonably hold: *Hii Chii Kok* at [56]. Thus, the question is not whether the court should *prefer* the evidence of one expert over another. Nor is the court to decide which is the *best* or *most reasonable* interpretation. Differences of opinion are bound to exist amongst medical experts and courts should not "play at being doctors": *Khoo James* at [3]:

> We state at the outset that this court would politely decline the invitations of both counsel to enter the fray that is the arena of divided medical opinion. … a lawyer-judge undertakes such an enterprise at his own peril. As the appeals have aptly demonstrated, medical arguments often take on a life of their own. Riposte follows rebuttal, as no two doctors seem to agree on the thorny issues that inhabit the frontiers of medical science … neither this court nor any other should have any business vindicating or vilifying the acts of medical practitioners. It would be pure humbug for a judge, in the rarefied atmosphere of the courtroom and with the benefit of hindsight, to substitute his opinion for that of the doctor in the consultation room or operating chamber. We often enough tell doctors not to play god; it seems only fair that, similarly, judges and lawyers should not play at being doctors.

104 However, it would equally be inappropriate to treat every possible view as acceptable. The *Bolitho* addendum thus imposes a threshold test of logic (*Bolitho* at 241–243):

> … the court is not bound to hold that a defendant doctor escapes liability for negligent treatment or diagnosis just because he leads evidence from a number of medical experts who are genuinely of opinion that the defendant's treatment or diagnosis accorded with sound medical practice. … *the court has to be satisfied that the exponents of the body of opinion relied upon can demonstrate that such opinion has a logical basis.* In particular in cases involving, as they so often do, the weighing

Version No 1: 27 Oct 2020 (22:41 hrs)

> of risks against benefits, *the judge before accepting a body of opinion as being responsible, reasonable or respectable, will need to be satisfied that, in forming their views, the experts have directed their minds to the question of comparative risks and benefits and have reached a defensible conclusion on the matter.*
>
> …
>
> … in cases of diagnosis and treatment there are cases where, despite a body of professional opinion sanctioning the defendant's conduct, the defendant can properly be held liable for negligence … In my judgment that is because, *in some cases, it cannot be demonstrated to the judge's satisfaction that the body of opinion relied upon is reasonable or responsible.* In the vast majority of cases the fact that distinguished experts in the field are of a particular opinion will demonstrate the reasonableness of that opinion. In particular, where there are questions of assessment of the relative risks and benefits of adopting a particular medical practice, a reasonable view necessarily presupposes that the relative risks and benefits have been weighed by the experts in forming their opinions. But *if, in a rare case, it can be demonstrated that the professional opinion is not capable of withstanding logical analysis, the judge is entitled to hold that the body of opinion is not reasonable or responsible.*
>
> I emphasise that in my view it will very seldom be right for a judge to reach the conclusion that views genuinely held by a competent medical expert are unreasonable. The assessment of medical risks and benefits is a matter of clinical judgment which a judge would not normally be able to make without expert evidence. … *it would be wrong to allow such assessment to deteriorate into seeking to persuade the judge to prefer one of two views both of which are capable of being logically supported. It is only where a judge can be satisfied that the body of expert opinion cannot be logically supported at all that such opinion will not provide the benchmark by reference to which the defendant's conduct falls to be assessed.*
>
> [emphasis added]

105 The facts of *Bolitho* illustrate the application of this test. In that case, a two-year-old boy was hospitalised for respiratory difficulties. At 12.40 pm the next day he suffered a bout of breathing difficulties, for which the nurse called a doctor by telephone but the doctor did not attend. The boy recovered but suffered a second bout of breathing difficulty at 2 pm. Again the nurse called a

Version No 1: 27 Oct 2020 (22:41 hrs)

doctor but the boy recovered without incident. At 2.30 pm the boy collapsed due to respiratory system failure and suffered a cardiac arrest. By the time his respiratory and cardiac functions were restored, he had sustained severe brain damage and he subsequently died. Proceedings were brought, alleging negligence, against the defendant's health authority. The contention was that any competent doctor would have arranged for prophylactic intubation after the second episode so as to provide an airway and that this procedure would have avoided the cardiac arrest and subsequent injury. The House of Lords applied the *Bolitho* addendum to hold that the omission to intubate the boy was not negligent (at 243–244):

> … is plainly not a case in which Dr. Dinwiddie's [the defendant's expert's] views can be dismissed as illogical. According to the accounts of [the nurses], although [the boy] had had two severe respiratory crises, he had recovered quickly from both and for the rest presented as a child who was active and running about. Dr. Dinwiddie's view was that these symptoms did not show a progressive respiratory collapse and that there was only a small risk of total respiratory failure. Intubation is not a routine, risk-free process. Dr. Roberton, a consultant paediatrician at Addenbrooke's Hospital, Cambridge, described it as 'a major undertaking - an invasive procedure with mortality and morbidity attached - it was an assault.' It involves anaesthetising and ventilating the child. A young child does not tolerate a tube easily 'at any rate for a day or two' and the child unless sedated tends to remove it. In those circumstances it cannot be suggested that it was illogical for Dr. Dinwiddie, a most distinguished expert, to favour running what, in his view, was a small risk of total respiratory collapse rather than to submit Patrick to the invasive procedure of intubation.

106 In Singapore, the *Bolitho* addendum has been interpreted as involving a two-stage test whereby:

(a) The court must be satisfied that the expert had directed his mind to the comparative risks and benefits relating to the matter. Bare and unsupported assertions would therefore fail the test at this stage.

Version No 1: 27 Oct 2020 (22:41 hrs)

(b) The expert must have reached a defensible conclusion, in the sense of being both internally consistent and not contradicted by proven extrinsic facts.

107 The overall enquiry is whether the analysis of the expert's opinion has a logical foundation, being based on sufficiently comprehensive reasons that are not obviously unsustainable: *Hii Chii Kok* at [59]–[60].

108 The *Bolam-Bolitho* test applies even to "pure diagnosis" cases where what is alleged to be negligent is the doctor's diagnostic decision itself, with no decision made about treatment or further diagnostic procedures. It is axiomatic that questions of *pure fact* must be answered by the court without recourse to the *Bolam-Bolitho* test. Any subsequent diagnosis that incorporates interpretation and opinion must be measured against a reasonable standard of care as understood by the medical professionals (*Noor Azlin bte Abdul Rahman v Changi General Hospital Pte Ltd and others* [2019] 1 SLR 834 ("*Noor Azlin*") at [63]). Although this is not a "pure diagnosis" case, the principles stated in *Noor Azlin* apply insofar as the First Defendant's course of treatment was premised on his interpretation of the First CT Scan and the Plaintiff alleges negligence with regard to the latter.

109 It should be noted that in *Hii Chii Kok*, the Court of Appeal, apart from retaining the *Bolam-Bolitho* test for the medical functions of diagnosis and treatment, also stressed that "in the specific context of surgery, it will often be the case that more latitude will be afforded to the surgeon than is afforded to a doctor in perhaps any other setting". The full passage reads (*Hii Chii Kok* at [102]):

> … Moreover, in the specific context of surgery, it will often be the case that more latitude will be afforded to the surgeon than

Version No 1: 27 Oct 2020 (22:41 hrs)

> is afforded to a doctor in perhaps any other setting. Behind the doors of the operating theatre lies a dynamic scene where there is often the greatest actual danger to the patient and where it is often the most difficult and potentially the most unfair to second-guess what the surgeon ought to have done. Of course, where a complaint against a surgeon concerns his pre-meditated selection of a particular procedure or technique, or for his care in carrying out the planned surgery, there may not be a need to afford him any special degree of latitude. But where a decision is made on the fly in response to a complication that arises in the course of the surgery, the court will be understandably hesitant to lay blame at the surgeon's door when his peers would not do so.

110 With these principles in mind, I turn to the post-operative issues raised by the Plaintiff.

Post-operative monitoring and care of the Plaintiff

111 The Plaintiff's case is that there was a failure to monitor with sufficient frequency the Plaintiff's vital neurological parameters, namely, GCS score, pupil size, and motor strength. This led to a failure to order a CT scan earlier at either 1655 hrs or 1730 hrs, which could have caught the Plaintiff's deterioration at an earlier stage and improved her chances of recovery. The Plaintiff also alleges that there was a failure to record all the neurological parameters in the neurological observation chart ("NOC"), which reflected an "organisational failure" in its system.[124] I shall deal with this issue first.

Failure to record all neurological observations in a single document

112 Several of the Plaintiff's documents are relevant here:

---

124 PCS at para 41.

Version No 1: 27 Oct 2020 (22:41 hrs)

(a) The NOC, also known as the consciousness level chart.[125] The NOC is a standard template with blank squares for medical personnel to tick or otherwise make entries to record the patient's GCS score, pupil size, and motor strength. The Plaintiff's NOC had only one neurological observation entry made at 1510 hrs.

(b) The recovery room records ("RRR").[126] The RRR is also a standard template with blank squares for medical personnel to make pertinent entries and to monitor the patient's condition after the surgery. To that end, many of the patient's vital parameters are recorded in the RRR, such as sedation score, pupil size, consciousness, temperature, respiratory rate, pain score, blood glucose, oxygen intake, *etc.* There is also a post-anaesthesia discharge scoring key table. The RRR for the Plaintiff was filled in fairly regularly at about 15-minute intervals, at 1452 hrs, 1505 hrs, 1520 hrs, 1535 hrs, 1550 hrs, 1605 hrs and 1620 hrs. Notably, the Plaintiff's RRR also had an additional handwritten row recording her GCS score at the abovementioned intervals. However, pupil size was recorded as "-" throughout. In the absence of any evidence from the Defendants of the significance of this, I can only infer that pupil size was not monitored at these timings. The RRR also did not record the Plaintiff's motor strength.

(c) The MPNs.[127] These record the patient's progress and indicate the date and time, treatment orders, and actions taken. MPNs allow doctors and nurses to make free text entries. The Plaintiff's MPNs record

125 DBD at p 163.

126 DBD at p 217.

127 DBD at pp 84–85.

Version No 1: 27 Oct 2020 (22:41 hrs)

her motor strength, which was recorded regularly at half-hour intervals around 1655–1700 hrs, 1730 hrs, 1800–1805 hrs and 1820 hrs. The Plaintiff's pupil size was recorded at 1655 hrs and 1820 hrs, while GCS was recorded at 1655 hrs, 1730 hrs, 1805 hrs and 1820 hrs.

113 The Plaintiff argues that the failure to record all her neurological parameters in the NOC fell below the standard of care.[128] PW3 Dr Gan testified that the failure to enter hourly entries on the NOC was not in accordance with standard medical practice.[129] The NOC was critical as it would have all the data recorded in one place. Similarly, PW5 Dr Tang testified that it was not enough to fill in the RRR in lieu of filling in the NOC, because the NOC captures succinctly in one document the whole picture of the patient's neurological progress. It was "very tedious" to have to refer to two separate documents.[130] The Plaintiff emphasised that having all relevant information in one place was especially crucial because NUH operated on the basis of team-based care, with patients seeing a "revolving door" of medical personnel such that there was a higher chance of information slipping through the cracks if it was recorded in different places.[131]

114 It would have been ideal and a good practice for the Plaintiff's neurological parameters to have been consolidated in the NOC instead of having the neurological parameters scattered across her other medical records. However, from the evidence, I do not find that the failure to record all the

---

128 PCS at paras 50–54.

129 25/4/19 NE 26.

130 10/5/19 NE 139–145.

131 PCS at para 53.

Version No 1: 27 Oct 2020 (22:41 hrs)

Plaintiff's parameters in the NOC is *ipso facto* a breach of proper patient care. The fundamental issue must be whether, in substance, the Plaintiff was well cared for post-operatively by the Defendants and their team members. In other words, were her neurological and other vital signs and parameters closely monitored? If, indeed, these were done and the Defendants' medical personnel took good care of the Plaintiff, it would be extremely difficult for the Plaintiff to argue convincingly that the Defendants were negligent by having fallen below the requisite standard of post-operative care. Conversely, the Defendants would not be exonerated from negligence if they had faithfully filled in the NOC but had not actually referred to or taken into account the relevant information in their decision-making or failed to act when the Plaintiff's clinical condition deteriorated.

115 The Plaintiff cited the case of *Noor Azlin*,[132] where the Court of Appeal found (at [99]) that the hospital breached its duty of care to ensure proper follow-up on a patient because, amongst others:

> … *the system put in place by CGH to review radiological reports was inadequate because it did not allow for the comprehensive management of a patient. In particular,* ***there was no appropriate mechanism for the consolidation of what was already known.*** Each time the Appellant attended at the A&E department, and each time a radiological report on her nodule was prepared, it was seemingly treated as an isolated incident. There was no evidence of any consolidation of what was already known about her. If the A&E doctor reviewing the radiological report had checked against Dr Imran's notes, for example, it would have become immediately obvious to him that the only specialist who had seen her over the past four years had mistakenly concluded that the opacity was resolving or had resolved, and the A&E doctor would have come to the conclusion that the nodule had been persistent and had not been properly assessed by a specialist. Under these circumstances, it would have been unreasonable to conclude

132 PCS at para 42.

Version No 1: 27 Oct 2020 (22:41 hrs)

> that no follow-up was necessary. However, as Dr Yap explained, the A&E doctors did not have access to Dr Imran's medical notes. … [emphasis added in italics and bold italics]

This passage does not support a contention that the failure to record all the Plaintiff's vital parameters in a single document was negligent. The context in *Noor Azlin* was that of *multiple consultations* and follow-up appointments in *various departments* in the hospital over time, which made the need for a mechanism to consolidate information particularly significant. In contrast, here we are concerned with what occurred over mere hours and all the information regarding the Plaintiff are in her medical folder in her ward, albeit in different documents.

116 Accordingly, I do not accept that the mere failure to record all observations in a single document falls below the standard of care. What is critical must be substance over form, though I acknowledge that as a matter of good practice the NOC should have been properly completed and all neurological observations should have been recorded there. I shall address the issue of whether the Second Defendant's post-operative care of the Plaintiff had fallen below the required standard of care.

Monitoring of the Plaintiff's condition after the First Surgery

117 The sub-issues here are:

(a) Was the direction for hourly monitoring adequate?

(b) Was the direction for hourly monitoring complied with?

(c) Was there a non-delegable duty of care on the First Defendant's part to monitor the Plaintiff after the First Surgery?

Version No 1: 27 Oct 2020 (22:41 hrs)

(1) Adequacy of direction for hourly monitoring

118 The parties do not dispute that the post-operative instructions were for the monitoring of the Plaintiff on an hourly basis and the findings were to be recorded in the NOC. This would have been the default instruction from the doctor rather than a special instruction given by the First Defendant.[133] Was this direction for hourly monitoring of the Plaintiff, who had undergone major brain surgery, adequate?

119 PW3 Dr Gan testified that the parameters of GCS and limb score should be "very strictly monitored" in view of the higher-than-normal risk of haemorrhage.[134] Monitoring should have been done every 15 to 30 minutes for at least the first two hours, with time intervals to be lengthened if the patient was stable.[135] DW4 Dr Ivan Ng agreed that observations should be done at much closer intervals, though not as frequent as once every 15 minutes to half an hour.[136]

120 On the other hand, DW3 Dr Hong testified that while the risk of haemorrhagic complications due to venous haemorrhage after surgical removal of a large tumour would be higher, "standard vigilance" would be fine and there was no such thing as more vigilance just because the tumour was cystic.[137] DW3 Dr Hong further added that if there were neurological changes in the patient the

133 15/5/19 NE 19 lines 7–11.

134 25/4/19 NE 9–11.

135 25/4/19 NE 13–14, 26.

136 10/7/19 NE 215.

137 8/7/19 NE 100.

Version No 1: 27 Oct 2020 (22:41 hrs)

regularity may be changed, and that was a decision for the attending surgeon.[138] DW3 Dr Hong opined that when the Plaintiff's limb power fell to zero (at 1655 hrs), he would go back after 15 to 20 minutes to make sure the patient was fine, *but this did not in his view mean that hourly monitoring was inadequate*.[139]

121 I agree with DW3 Dr Hong that standard vigilance in the form of hourly monitoring in this case was adequate unless the Plaintiff's clinical condition warranted closer monitoring. I do not accept the Plaintiff's submission that a higher standard of care (with more frequent monitoring) was necessary because this was a case of an elevated risk of haemorrhage.[140] The First Surgery for tumour removal was a success and uneventful. There was no reason for the First Defendant and his team to suspect that anything was amiss or going to go awry in relation to the Plaintiff. In this regard, I do not accept PW1 Ms Chiam's contentions regarding the Plaintiff's condition at 1510 hrs.

122 PW1 Ms Chiam alleges that the Plaintiff was "not responsive" after the First Surgery.[141] According to PW1 Ms Chiam, as the Plaintiff was wheeled out of the operating theatre, the Plaintiff's family proceeded straight towards her. The nurse allowed the Plaintiff's family to stand next to the Plaintiff and talk to her. Although they called out to the Plaintiff, she was not responsive. Her eyes were open and her eyeballs were jerking spontaneously.

123 PW1 Ms Chiam's allegations are contradicted by the contemporaneous medical records. The medical records show that when the Plaintiff left the

---

138 8/7/19 NE 102.

139 8/7/19 NE 167.

140 PCS at para 49.

141 PW1 Chiam Yu Zhu's AEIC at para 59.

Version No 1: 27 Oct 2020 (22:41 hrs)

operating theatre and was in the recovery room between 1505 hrs and 1620 hrs, the Plaintiff had a full GCS score of 15. This was documented by the nurses in the recovery room.[142] A full score of 15 means that the Plaintiff was fully alert and conscious, as opposed to "unresponsive" as alleged by PW1 Ms Chiam. The medical records supported the First Defendant's position on this issue. The First Defendant stated that shortly after the First Surgery, he examined the Plaintiff along with DW12 Dr Low. They found her to be well and alert. Furthermore, her facial nerves were intact.[143]

124 PW1 Ms Chiam's allegations are also inconsistent with how the family behaved on 3 June 2014. When the First Defendant spoke to the Plaintiff's family one day after the First Surgery (*ie*, 3 June 2014), he mentioned that the Plaintiff was observed to be neurologically sound after the First Surgery while she was in the recovery room.[144] If the Plaintiff had indeed been unresponsive with her eyes jerking spontaneously, it would have been natural for her family members to inform the First Defendant and they would have sought clarification from him. But this was not the evidence before me.

125 Therefore, I am unable to accept PW1 Ms Chiam's allegations on the condition of the Plaintiff immediately after the First Surgery. The Plaintiff was alert and conscious after the First Surgery and there was no cause for exceptional concern. For these reasons, the direction for "Hrly CLC and parameters" monitoring[145] was adequate.

---

142 DBD at p 217.

143 Dr Yeo's AEIC at para 42.

144 DBD at p 215.

145 DBD at p 222.

Version No 1: 27 Oct 2020 (22:41 hrs)

(2) Was the Second Defendant negligent because it failed to take the Plaintiff's neurological parameters at 1610 hrs?

126 The Plaintiff alleges that "it is critical that patients in the post-operative period have *all* of their neurological parameters as set out in the [NOC] monitored and recorded *on an hourly basis* ... These parameters are not limited to GCS monitoring but also include pupil size and reaction, blood pressure and pulse rate, respiration, and limb power of all four limbs" [emphasis in original].[146] It is not disputed that there is only one entry at 1510 hrs in the NOC. But, adopting a substance over form approach (see [114]–[116] above), does the omission of the 1610 hrs entry (*ie*, one hour after 1510 hrs) mean that these parameters were not monitored around that time? To the contrary. I shall deal with the parameters raised by the Plaintiff in turn. Firstly, GCS. The Plaintiff's GCS was monitored around 1605 hrs. In fact, from the NOC, MPNs and RRRs, the Plaintiff's GCS was monitored at 1452 hrs, 1505 hrs, 1510 hrs, 1520 hrs, 1535 hrs, 1550 hrs, 1605 hrs, 1620 hrs, 1655 hrs, 1730 hrs, 1805 hrs and 1820 hrs – which is much more regularly than the prescribed one-hour intervals.

127 Secondly, the monitoring of the Plaintiff's blood pressure, pulse rate and respiration. I find that there was no missed reading around 1610 hrs. While the Plaintiff was in the recovery room the RRR shows that her blood pressure, heart rate and oxygen flow were regularly monitored at 1452 hrs, 1505 hrs, 1520 hrs, 1535 hrs, 1550 hrs, 1605 hrs and 1620 hrs.[147] These continued to be monitored once she was transferred to the HDU. DW5 Dr Yang's evidence was that at the HDU these were *continuously* monitored using, amongst others, a blood pressure cuff, oxygen level monitor and intra-arterial (IA) line and displayed on

146 PCS at para 50.

147 DBD at p 217.

Version No 1: 27 Oct 2020 (22:41 hrs)

a screen that was visible to the medical personnel attending to the Plaintiff, even if this was not noted down in hardcopy.[148]

128 Thirdly, pupil size. The Plaintiff's pupil size was monitored at 1510 hrs, 1655 hrs, and 1820 hrs. While there was no record of pupil size around 1610 hrs, it must be recalled that at 1605 hrs and 1620 hrs the Plaintiff was GCS 15. DW3 Dr Hong's evidence was that "[i]f someone is alert, someone is wide awake and talking to you, [the doctor] probably wouldn't look at the pupils because you are doing an examination looking at the patient".[149] The evidence of PW3 Dr Gan[150] and DW4 Dr Ivan Ng[151] was to similar effect. That is an acceptable clinical approach. In this regard the case of *Hayes v Royal Col Hospital* 2001 BCSC 1047 at [96] is helpful. In that case, the court found that, notwithstanding the nurse's failure to record her observations after the first reading, the "combined formal and informal assessments were effectively equivalent to the Protocol requirements" and "would have revealed … neurological changes or signs almost immediately the intra-cranial hemorrhaging began".

129 Fourthly, limb power. The Plaintiff's motor strength was recorded at 1510 hrs, 1655 hrs–1700 hrs, 1730 hrs, and 1800 hrs–1805 hrs. Although there was no record at 1610 hrs of limb power specifically, the Second Defendant contends that in assessing the motor component of the Plaintiff's GCS, the nurse in the recovery room, DW13 Nurse Kym Canto ("DW13 Nurse Canto") had asked the Plaintiff to raise all four limbs and the full score for the motor

148 12/7/19 NE 41-42.

149 8/7/19 NE 139.

150 25/4/19 NE 18.

151 10/7/19 NE 204.

Version No 1: 27 Oct 2020 (22:41 hrs)

component for the GCS readings around that time meant that she could do so.[152] DW13 Ms Canto's testimony was that:[153]

> … I acknowledge that I didn't put up 4.10 in the neurological chart [NOC], but I put on the recovery room chart the GCS of the patient. So the motor response is there also. So the patient is obeying commands. *We ask the patient to move up his both upper arms and both upper legs so the patient is obeying commands*. I put there on my chart 16:05 to 16:20 so the patient is okay. She is GCS 15, she is obeying commands. *She can raise up both arms and both legs*. [emphasis added]

130 In response, the Plaintiff contends that: (i) the Second Defendant glossed over how GCS only records the best motor response of a patient,[154] and (ii) the Second Defendant conflated limb power and the motor component of GCS when the two are not interchangeable. The motor component tests only whether a patient can move on command, while limb power is an actual measurement of limb strength. Limb power records a gradation from no movement for a period of time (score of 0), a flicker of movement (score of 1), lifting up only against gravity (score of 3), ability to lift but displaying weakness and giving way when pressure is applied (score of 4), to lifting against resistance (score of 5).[155] The Plaintiff points out that DW13 Nurse Canto admitted to not being able to recall the Plaintiff's limb power at all,[156] such that applying the approach in *Surender Singh s/o Jagdish Singh and another (administrators of the estate of Narindar Kaur d/o Sarwan Singh, deceased) v Li Man Kay and others* [2010] 1 SLR 428 ("*Surender Singh*") and *Noor Azlin*, the court should

---

152 SDDCC at para 71(g).

153 19/7/19 NE 180.

154 PCS at paras 58b-c and 61.

155 10/5/19 NE 203-204.

156 19/7/19 NE 182.

Version No 1: 27 Oct 2020 (22:41 hrs)

find against the Second Defendant as there is "no proof either way" that the relevant monitoring had been done.[157]

131 I do not accept either of the Plaintiff's contentions. Although GCS indeed only records the patient's best motor response, DW13 Nurse Canto had gone beyond that as seen from her explanation that she asked the Plaintiff to raise *all four* limbs. Further, the present case is distinguishable from *Noor Azlin* and *Surender Singh* because in both cases there was a complete dearth of evidence from the defendant hospital. In *Noor Azlin* the court explained its findings as follows (at [97]):

> The Judge noted that there had been a gap in the evidence as to whether the follow-up process on the radiological report had been carried out in the present case. It was held, on a balance of probabilities, that it had been followed because there was no reason for CGH not to have done so in this particular case and it was also entirely plausible that the reviewing A&E senior doctor had decided not to recall the Appellant on the basis that the nodule was reported to be stable … With respect, we are unable to agree with this finding. In our view, since the Appellant has shown that *both* the April 2010 and July 2011 radiological reports recommended that follow-up on the nodule be carried out, the evidentiary burden shifts to CGH to show that it *did* follow up in some way. For example, this could be done by showing that a doctor did see the recommendation but chose not to follow it for good reason. However, there is a complete dearth of evidence in this regard. First, the X-ray request form had apparently been disposed of. But, even if it had been adduced, all that it would have shown was that the radiological report was routed back to the A&E department. It would not indicate if an A&E doctor did see, review, and conduct the necessary follow-up. Second, and more significantly, there was no record whatsoever of the senior doctor who had supposedly reviewed the radiological reports and who made the clinical decision not to recall the Appellant. ***Given the complete lack of evidence showing that some action was taken, we find, on a balance of probabilities, that the procedure that was in place was not adhered to and that CGH had therefore failed to ensure that there***

---

157 PCS at para 61.

Version No 1: 27 Oct 2020 (22:41 hrs)

> ***was proper follow-up for the Appellant's case.*** [original emphasis in italics; emphasis added in bold italics]

In similar vein, it was significant in *Surender Singh* that the nurse attending to the patient was not called as a witness, with the result that her affidavit was rejected leaving the hospital with no evidence on post-operative monitoring (*Surender Singh* at [210] and [215]). That is not the case here; the Second Defendant had called DW13 Nurse Canto who testified that she *had* checked the Plaintiff's limb-raising. Accordingly, I do not accept that the Plaintiff's parameters were not monitored at 1610 hrs, taking a substance over form approach.

132 Even if there was, contrary to my findings at [128]–[131], omissions in monitoring the Plaintiff's parameters (pupil size and limb power) at 1610 hrs, those omissions must be looked at in totality and in context. I acknowledge that in some circumstances, a single act or omission may constitute negligence or even gross negligence. The paradigm example is a distracted doctor who leaves a surgical instrument inside the patient after an operation. But such a single lapse that precipitated a life-or-death situation, is very far removed from the present case. The overall picture is that of consistent and adequate monitoring, which (as I shall elaborate on below) allowed for the Second Defendant's personnel to respond quickly and decisively when the Plaintiff deteriorated at 1820 hrs. While recovering from the First Surgery in the recovery room, she was conscious with GCS 15. A perusal of the RRR shows that the medical team that had attended to the Plaintiff was monitoring her vital parameters, including her GCS score at about half an hour intervals from 1452 hrs to 1620 hrs. The Plaintiff was reviewed again at 1655 hrs when she was moved from the recovery room to the HDU. Further, when her GCS dropped by two points and she had right hemiplegia, a nurse had alerted the doctor. DW15 Dr Lu and DW5

Version No 1: 27 Oct 2020 (22:41 hrs)

Dr Yang then attended to her at 1730 hrs. Her condition improved and the medical team continued to monitor her. At 1805 hrs the Plaintiff's GCS dropped to 12, triggering the giving of immediate attention to her. At 1820 hrs when her GCS dropped to 10 it became an emergency. From these events it can be seen that notwithstanding the instruction of hourly monitoring the Plaintiff was actually monitored even more closely, as evidenced by how *immediate* attention was given when her clinical condition started to deteriorate. This case is distinguishable from *Surender Singh* (cited by the Plaintiff), where there was no evidence of monitoring between 1430 hrs and 1600 hrs–1615 hrs when hourly monitoring should have been done at 1530 hrs, and that apparently led to irreversible decline that was *not picked up by the hospital until the deceased's family alerted a nurse*. Thus, I am satisfied that the frequency of the Plaintiff's monitoring was adequate and the failure to observe the Plaintiff's pupil size and limb power at 1610 hrs, even if proven, did not *per se* fall below the standard of care.

133 Accordingly, the Second Defendant was not negligent in the post-operative monitoring of the Plaintiff.

(3) The First Defendant's liability for any failure to monitor

134 The Plaintiff alleges, in closing submissions, that the First Defendant as the lead surgeon for the First Surgery owed a non-delegable duty to ensure that his team adequately monitored the Plaintiff post-operatively.[158] This is because the five factors at [58] of *Management Corporation Strata Title Plan No 3322 v Tiong Aik Construction Pte Ltd and another* [2016] 4 SLR 521 ("*Tiong Aik*")

158 PCS at para 46.

Version No 1: 27 Oct 2020 (22:41 hrs)

are met. Consequently, the First Defendant is liable to the Plaintiff for his team's negligence.

135 Whether the First Defendant owes the said non-delegable duty to the Plaintiff is a moot point, given my finding that there was no negligence on the part of his team or the Second Defendant. Non-delegable duty was also not pleaded, but only mentioned in passing in the Plaintiff's opening statement.[159] For completeness, however, I shall explain why it is highly doubtful that a non-delegable duty could be imposed on the First Defendant.

136 In *Tiong Aik*, the Court of Appeal explained the nature of non-delegable duties in tort as follows (at [19]–[21]):

> … in the context of the tort of negligence, a person is generally only held liable for his own carelessness, and not for the carelessness of others. …
>
> … Vicarious liability stands, in a sense, as a derogation from this principle … It permits the imputation of secondary tortious liability *on an employer* on the basis of its employee's primary tortious liability … The employer is liable not because of its own negligence, but because of its employee's negligence. *The principles of vicarious liability, however, do not extend to imposing liability on employers for the negligence of their independent contractors.* … An employer may thus raise the independent contractor defence (ie, that the negligent party was an independent contractor, not an employee) against a claim of vicarious liability.
>
> … ***A separate legal basis for such a cause of action may, however, exist in the doctrine of non-delegable duties***. The liability incurred upon a breach of a non-delegable duty is not vicarious … Non-delegable duties are personal duties, the delegation of which will not enable the duty-bearer to escape tortious liability because the legal responsibility for the proper performance of the duty resides, in law, in the duty-bearer …

159 17/4/19 NE 105.

Version No 1: 27 Oct 2020 (22:41 hrs)

> [original emphasis omitted; emphasis added in italics and bold italics]

137 The Plaintiff, with respect, has misunderstood the scope of the duty owed by the First Defendant, as illustrated by the case of *Elliott v Bickerstaff* [1999] NSWCA 453 ("*Elliott*"). In that case, the respondent patient sued the appellant surgeon for negligence for leaving a sponge in her abdominal cavity. A nurse had been keeping count of the number of sponges and wrongly assured the surgeon that the count was "satisfactory". In holding that the surgeon did not have a non-delegable duty of care, the court explained the importance of first ascertaining the scope of the duty of care (at [73], [82], and [98]–[103]):

> … the theatre staff were not the servants or agents of the appellant. They were employees of the hospital. In the absence of personal negligence, the finding of liability depended on the appellant owing a non-delegable duty of care to the respondent such that he was nonetheless liable for the failure of the theatre staff to keep proper count of the sponges used in the surgery. The trial judge referred to liability for 'the negligent act of leaving a sponge in the Plaintiff's abdominal cavity during the course of surgery which he was performing', holding the appellant liable for the act even though the negligence was that of the theatre staff. For the reasons which follow, in my opinion, *this misapprehended the extent of the appellant's liability.* …
>
> …
>
> … *If the defendant does not owe a duty of care to the plaintiff at all, a non-delegable duty of care can not be found … the care which the defendant must ensure that the third party exercises can not be greater in scope than would have been required of the defendant if the defendant had been fulfilling the duty of care.*
>
> …
>
> … the initial inquiry is into the scope of the duty of care owed by the appellant to the respondent: what medical services did he undertake to provide? Only when that has been ascertained should it be asked whether the duty of care was non-delegable, that is, whether the appellant was unable to fulfil his duty of care in providing those medical services by exercising reasonable care in entrusting performance to a competent third party, and is liable if the third party did not exercise due care. The scope of the duty of care will be largely determined by the

Version No 1: 27 Oct 2020 (22:41 hrs)

> facts, but against the background of what I have called divided responsibility in surgery involving a team.
>
> …
>
> … I do not think it can be said that the appellant undertook the provision to the respondent of "complete medical services" … *He did not undertake the provision of nursing services before or after the operation; they were to be provided by the hospital. There was nothing to suggest that he undertook the provision of the services of the anaesthetist. He did not undertake the provision of the services of the theatre staff, who were also to be provided by the hospital. He undertook the provision of his own surgical services, and there was nothing to indicate that he was to provide his surgical services otherwise than as one member of a team, the other members being the anaesthetist and the hospital staff, and in accordance with the normal procedure.*
>
> … On the evidence in this case, he was required to exercise reasonable care and skill in feeling for sponges in the abdominal cavity and asking whether the sponge count was satisfactory. *But he was entitled to rely on the theatre staff in the customary way, and on the evidence in this case I do not think that his duty of care relevantly extended beyond feeling for sponges in the abdominal cavity and asking whether the sponge count was satisfactory*. It follows that in my opinion the appellant was not in breach of a non-delegable duty of care by reason of the negligence of the theatre staff.
>
> … In the manner in which surgery of the kind undergone by the respondent is performed, the patient receives the attention of a team: the surgeon, the anaesthetist, and theatre staff. *There is divided responsibility. The surgeon can be regarded, in the phrase used by the respondent's counsel, as the master of ceremonies, but he is nonetheless a member of a team and reliant on the due discharge of their responsibilities by the other members of the team. He should be able to concentrate on his own skilled task without shouldering the responsibilities of the other members of the team.*
>
> [emphasis added]

138 Notwithstanding that the present case concerns post-operative management rather than intra-operative management, the reasoning in *Elliott* applies equally. With respect, I do not accept the Plaintiff's submission that it makes a difference that the First Defendant was also the Head of Department of

Version No 1: 27 Oct 2020 (22:41 hrs)

Neurosurgery at NUH, in addition to being the lead surgeon.[160] In any case, the Defendants' arguments against imposing a non-delegable duty on surgeons in the position of the First Defendant are persuasive.[161] The imposition of a non-delegable duty would fracture team-based practice and be excessively onerous. This concept would disregard the reality on the ground where a consultant must attend to many patients in a single day in a public hospital. Thus, the First Defendant did not owe a non-delegable duty to ensure his team was adequately monitoring the Plaintiff post-operatively when he was performing another surgery on a different patient.

What should have been done at 1655 hrs and 1730 hrs?

139 The Plaintiff contends that a doctor should have been alerted at 1655 hrs when the Plaintiff's GCS dropped to 13 and she became hemiplegic and that CT scans should have been ordered at 1655 hrs or failing that, 1730 hrs. I find that there was no negligence because a doctor was indeed alerted at 1655 hrs by DW14 Nurse Lee. When the doctors (DW15 Dr Lu and DW5 Dr Yang) arrived at 1730 hrs the Plaintiff's condition had improved such that they were justified in not ordering a CT scan.

(1) Plaintiff's condition at 1655 hrs

(A) WHETHER A DOCTOR WAS ALERTED

140 There is no dispute that a nurse should have alerted a doctor at 1655 hrs. This was PW5 Dr Tang's opinion[162] and the First Defendant himself accepted

---

160 PRS at para 37.

161 D1CS at para 129; D2CS at paras 77-79.

162 7/5/19 NE 20.

Version No 1: 27 Oct 2020 (22:41 hrs)

that it would be a serious lapse if a nurse had not alerted the doctor.[163] The only issue is whether this was in fact done.

141 I find that DW14 Nurse Lee had alerted a doctor (DW5 Dr Yang) on an urgent basis upon seeing the Plaintiff's clinical deterioration at 1655 hrs. DW14 Nurse Lee's evidence was that she alerted DW5 Dr Yang because she noted the serious development of right hemiplegia and drop in GCS from 15 to 13. She recorded in her notes that DW5 Dr Yang and DW15 Dr Lu *reviewed the Plaintiff* at 1730 hrs, though she did not specifically write down that she *alerted* DW5 Dr Yang. The Plaintiff takes issue with this, focusing on how DW14 Nurse Lee had noted down that she had asked DW5 Dr Yang to re-assess the patient at 1805 hrs. The Plaintiff contrasts these two situations and argues that the omission to note down that she had alerted DW5 Dr Yang meant that she did not.[164] When I perused DW14 Nurse Lee's retrospective notes[165] in the MPNs made at 2050 hrs about the events at 1655 hrs, 1730 hrs and 1805 hrs, the failure to mention specifically that she alerted DW5 Dr Yang does not mean that she did not do so. It is implicit, when she stated that DW15 Dr Lu and DW5 Dr Yang reviewed the Plaintiff, that she must have alerted them. So she did not state the obvious. Thus, I disagree with the Plaintiff's interpretation and inference drawn from the MPNs.

142 The Plaintiff also seizes on DW14 Nurse Lee's evidence that she would have had to tell a doctor anyway as part of the routine post-operative review whenever a patient (here, the Plaintiff) was transferred from the recovery room

---

163 15/5/19 NE 81-82.

164 PCS at para 81.

165 DBD at p 84.

Version No 1: 27 Oct 2020 (22:41 hrs)

to the HDU.[166] The Plaintiff contends that doctors were alerted as part of a regular post-operative review and not because DW14 Nurse Lee raised the alarm.[167] I do not accept that submission. It is significant that DW15 Dr Lu's evidence was that he was told by the nurse about the Plaintiff's history,[168] which is congruent with his explanation that he checked the patient to reassure the nurse that this was his assessment:[169]

> MR VERGIS: … were you aware that the nurse, at 1455 [*sic*] hours, had found that the patient had full-blown right hemiplegia?
>
> A: Yes.
>
> Q: Are you sure, doctor?
>
> A: I'm sure that's to what the nurse has communicated with me.
>
> Q: How are you sure that is what the nurse communicate to you, doctor?
>
> A: *That's why we will go and check the patients.*
>
> Q: Mmm?
>
> A: To reassure the nurse that this is my assessment at that time, at that moment of time.
>
> [emphasis added]

143 DW5 Dr Yang had stated that he had gone to see the Plaintiff because he was informed, as the on-call medical officer, that a new patient had arrived in the HDU.[170] But DW5 Dr Yang did not know whether DW15 Dr Lu was

---

166 19/7/19 NE 191–193.

167 PCS at para 82.

168 19/7/9 NE 221-222.

169 19/7/19 NE 225.

170 12/7/19 NE 46.

Version No 1: 27 Oct 2020 (22:41 hrs)

informed by a nurse to review the patient specifically[171] and I have already gone through DW15 Dr Lu's evidence above.

144 From the evidence of DW5 Dr Yang and DW15 Dr Lu, on a balance of probabilities, I accept that DW14 Nurse Lee did alert Dr Yang of the Plaintiff's GCS drop and hemiplegia. Furthermore, she was an experienced nurse in the neurological ward and would have known the significance of those parameters.

(B) SHOULD A CT SCAN HAVE BEEN DONE AT 1655 HRS?

145 The First Defendant, who gave a snap-shot opinion based only on the Plaintiff's clinical condition at 1655 hrs, and most of the experts except DW4 Dr Ivan Ng opined that a CT scan should have been done *at 1655 hrs* ***if a doctor had observed the same clinical presentation as DW14 Nurse Lee did.*** PW5 Dr Tang and PW3 Dr Gan opined that the two-point drop in the Plaintiff's limb power was very significant as this could have indicated the known risk of post-operative haemorrhage. It would then not be reasonable to adopt a wait-and-see approach.[172] DW3 Dr Hong's opinion was that he would also have ordered a scan at 1655 hrs (because the Plaintiff was hemiplegic *and* GCS 13).[173] Significantly, even the First Defendant eventually agreed that at 1655 hrs, a new right-sided weakness was something that should be investigated via a CT scan and that he would very likely have ordered a scan to err on the side of caution.[174] A true, as opposed to transient, GCS drop of two to three points (to GCS 13 or

---

171 12/7/19 NE 9.

172 25/4/19 NE 30-32.

173 9/7/19 NE 193–194.

174 15/5/19 NE 76-77, 132.

Version No 1: 27 Oct 2020 (22:41 hrs)

12) would be worrying.[175] The Plaintiff also cited several textbooks and articles in support of the view that a CT scan should have been ordered.[176]

146 DW4 Dr Ivan Ng, however, opined that at 1655 hrs he would not have ordered a CT scan for the Plaintiff despite a two-point drop in her GCS and a right hemiplegia. Instead he would have monitored the Plaintiff closely. He explained that generally a two-point drop in GCS would be a concern. However, in the Plaintiff's case she had a full score of 6 for motor response and a full score of 4 for eye response, though her verbal response had dropped by 2 points (*ie*, to 3 out of 5 points). This drop in verbal response would not have caused DW4 Dr Ivan Ng to send the Plaintiff for a CT scan. However, if there was a two-point drop in the motor response or eye response this would be a concern and a CT scan would be warranted. Although the Plaintiff also had right hemiplegia DW4 Dr Ivan Ng would still not have sent her for a CT scan because: [177]

> The presence of a right hemiplegia after surgery, in the absence of a drop in the E score or the M score of the GCS may be due to manipulation or may be due to other elements. And, of course, at that point in time the CT scan will not tell us where it is. The CT scan will only tell us whether there's blood or there's no blood. So, because of that, doing a CT scan would not help us in making any valuable decisions for the patient with regards to intervention.

DW4 Dr Ivan Ng further added that for a surgery involving the removal of a large tumour, some haemorrhage would be expected.

---

175 15/5/19 NE 30.

176 PCS at para 90.

177 11/7/19 NE 4.

Version No 1: 27 Oct 2020 (22:41 hrs)

147 But leaving aside the divergence of expert opinions, the reality of the matter is that DW14 Nurse Lee *could not* have ordered a CT scan for the Plaintiff at 1655 hrs, as according to NUH's protocol only a doctor could do so. The only thing she could have done was to alert a doctor and that was what she did. Shortly thereafter, the doctors arrived and by then the Plaintiff had improved at 1730 hrs. In view of that, the doctors decided to monitor her condition instead and this action cannot be faulted. Even the literature relied on by the Plaintiff does not go so far as to prescribe a CT scan even in the face of improvement; it only states that patients who show "progressive *deterioration* … or *worsening* neurological deficit should undergo immediate CT scanning" [emphasis added].[178] Hence, it was not necessary to send the Plaintiff for a CT scan as the Plaintiff showed positive signs of improvement by the time the doctors examined her.

148 Arising from the approach at [147] above, there is a subsidiary issue of whether a doctor should have arrived more quickly when alerted at 1655 hrs. According to DW14 Nurse Lee's notes in the MPNs she stated "Received patient, Mdm Goh Guan Sin from OT via trolley at 1655 hrs …". This means that the Plaintiff arrived at the HDU at 1655 hrs. After DW14 Nurse Lee settled the Plaintiff in HDU, she took the Plaintiff's GCS score and motor strength. Depending on how long DW14 Nurse Lee needed to do so, the examination of the Plaintiff would take some time. However, there is no evidence on this. Thereafter, DW14 Nurse Lee alerted DW5 Dr Yang who came with DW15 Dr Lu to review the Plaintiff at 1730 hrs. The time for the doctors to respond would depend on what they were doing at that time and where they were. Thus,

---

178 Plaintiff's reply submissions ("PRS") at para 15.

Version No 1: 27 Oct 2020 (22:41 hrs)

there are several variables involved and it will be speculative to make any meaningful conclusion.

149 Be that as it may, the Plaintiff failed to adduce evidence that a 30-minute delay was too long a response time. The Plaintiff's counsel also did not pursue this angle in his cross-examination. This argument must fail as the onus is on the Plaintiff to prove her case. I am of the view that there was no lapse in caring for the Plaintiff, given the short response time of 35 minutes and the absence of evidence to suggest tardiness on the part of the doctors.

150 Was the Plaintiff's right hemiplegia at 1655 hrs a harbinger of the precipitous decline of the Plaintiff after 1800 hrs? Without prescience or the benefit of foresight, the answer is no as the Plaintiff's clinical condition improved by 1730 hrs.

(2) Plaintiff's condition at 1730 hrs

151 The next issue is whether the omission to order a CT scan at 1730 hrs after DW15 Dr Lu and DW5 Dr Yang came onto the scene fell below the standard of care. I find that it did not.

152 DW3 Dr Hong and DW4 Dr Ivan Ng testified that they would not have ordered a CT scan at 1730 hrs because the Plaintiff's condition was improving.[179] As DW3 Dr Hong explained, the "index of suspicion" for a large haematoma was not high at 1730 hrs, because a haematoma big enough to cause limb weakness would have affected the Plaintiff's consciousness level, but she

[179] 9/7/19 NE 193–194.

Version No 1: 27 Oct 2020 (22:41 hrs)

was alert at 1730 hrs.[180] The most likely reason for the Plaintiff's right-sided weakness at that stage would be post-operative swelling in the brainstem tissue. The fluctuations in GCS that the Plaintiff exhibited were due to fluctuations in oedema.[181] Swelling would be treated with steroids, which is in fact what was done with the prescription of Dexamethasone. Close observation was thus more appropriate than ordering a CT scan.[182]

153 PW5 Dr Tang and PW3 Dr Gan stated that they would have ordered a CT scan at 1730 hrs due to the drastic drop in limb power from the Plaintiff's baseline of 5/5 before 1655 hrs and right after the operation.[183] It did not matter that GCS had gone up to 15 at 1730 hrs because the overall picture (*ie*, limb power and not only GCS) must be taken into account. It was not reasonable to elect to monitor simply because the patient was alert and responsive to commands.[184]

154 The opinions of the Plaintiff's and Defendants' experts are diametrically opposite. Applying *Bolam-Bolitho*, it is not for this court to decisively conclude one way or another whether a CT scan should have been ordered at 1730 hrs. This court must decide whether the decision of the Second Defendant's doctors in not ordering a CT scan at 1730 hrs is supported by a responsible body of experts' opinions within the profession and that the opinion is reasonable and logical, even if there is another body of expert opinion that disagrees.

---

180 8/7/19 NE 117–118.

181 10/7/19 NE 70–71.

182 10/7/19 NE 8.

183 7/5/19 NE 14-21, 51.

184 26/4/19 NE 112.

Version No 1: 27 Oct 2020 (22:41 hrs)

155 In my view, the Defendants' experts constitute a body of expert opinions that is logical, reasonable and tenable. The Plaintiff's neurological parameters at 1655 hrs were GCS 13 (drop of 2 points), right hemiplegia and motor strength of 3/2 in her left limbs. At 1730 hrs the Plaintiff was GCS 15, an improvement of 2 points and the maximum possible score. Her motor strength had also recovered, with her right limb power improving from 0/0 to 3/1 and her left limb power increased from 3/2 to 4/4. Overall, her neurological condition had improved substantially. A logical and reasonable treatment approach at 1730 hrs was to monitor the Plaintiff's condition and to treat her symptomatically with steroids, which was done in this case. I do not accept the Plaintiff's contention that because of a missed reading at 1610 hrs, a doctor must err on the side of caution and order a CT scan. I have already addressed the significance of this omission and whether it was negligent.

156 The Plaintiff alleges that DW15 Dr Lu failed to order a CT scan at 1730 hrs because he had not checked her records when he reviewed her at that time. This led to him mistakenly considering her *right*-sided weakness as a pre-existing one when the notes of the 15 May 2014 Consultation[185] recorded that the only pre-existing weakness was in her *left* lower limb.[186] In other words, he failed to appreciate the worsening neurological deficit from 1510 hrs that would, in the Plaintiff's submission, have warranted a CT scan being done. The Plaintiff relied on the portion of DW15 Dr Lu's affidavit which stated that he "attributed her right-sided weakness to her pre-operative weakness and the fact that she just had surgery".[187]

---

185 DBD at p 12.

186 PCS at para 67.

187 PCS at para 69; DW15 Dr Lu's AEIC at para 38.

Version No 1: 27 Oct 2020 (22:41 hrs)

157 I find that DW15 Dr Lu was not mistaken or operating under any mistaken assumption about the improvement of the Plaintiff's clinical condition. While DW15 Dr Lu admitted to not reviewing the NOC, he stated that this was because the nurse had briefed him and brought him up to speed about the Plaintiff's condition. He said this was a more efficient way to find out about the Plaintiff's medical history quickly.[188] DW15 Dr Lu was not attending to the Plaintiff for the very first time at 1730 hrs. He had known about the Plaintiff's medical history before the First Surgery. This was as early as the 15 May 2014 Consultation when he was one of the doctors in attendance when the Plaintiff consulted DW9 Dr Ho about the tumour in her brain.[189] He had also attended the Department Meeting on 22 May 2014 at which the Plaintiff's case was discussed.[190] He also reviewed the Plaintiff the night before the First Surgery on 1 June 2014[191] and reviewed the Plaintiff at the recovery room after the First Surgery.[192] Thus, DW15 Dr Lu was not coming in "cold".

158 DW15 Dr Lu further explained that although he noted the Plaintiff's right-sided weakness at 1730 hrs, he did not order a CT scan as the Plaintiff had been assessed to be weak pre-operatively, and he expected this weakness to persist after the First Surgery.[193] He explained, during cross-examination, that he used the term "pre-operative weakness" to describe the Plaintiff's right-sided weakness because this was opposite-side weakness that was to be expected from

---

188 197/719 NE 222, 224.

189 DW15 Dr Lu's AEIC at para 4.

190 DBD at p 21.

191 DW15 Dr Lu's AEIC at para 17.

192 DW15 Dr Lu's AEIC at paras 29–30.

193 DW15 Dr Lu's AEIC at para 35.

Version No 1: 27 Oct 2020 (22:41 hrs)

the tumour (pre-operatively) pressing against the Plaintiff's pons on the left side:[194]

> Q: Can you explain what you mean here is that you thought that her right side weakness was a pre-existing condition?
>
> A: Because still -- based on the MRI findings, the patient have a huge CP angle tumour on the left side, usually it will compress on the motor track on the opposite side which I presume the patients have a weakness on the right side to begin with, yeah.

In re-examination, DW15 Dr Lu added that the continued weakness was possibly attributable to oedema around the dissection area, for which he directed that steroids be continued.[195]

159 A further basis for him forming the impression that the Plaintiff had pre-operative lower limb weakness was the nurse's entry in the Plaintiff's medical records for 1 June 2014, which stated "Pt's b/l LL is weak, needs assistance in ADLs" (*ie*, patient's *bilateral* lower limbs are weak and she needs assistance in activities of daily living).[196]

160 Therefore, I find that even if DW15 Dr Lu might not have known or recalled at 1730 hrs that the Plaintiff had existing "mild weakness in left LL power 4" (as recorded in the MPN[197] on 15 May 2014), this would not have changed DW15 Dr Lu's decision to monitor the Plaintiff instead of ordering a CT scan for the Plaintiff at 1730 hrs. Thus, DW15 Dr Lu's management of the

---

194 19/7/19 NE 218.

195 19/7/19 NE 230-231.

196 DBD at p 71; 19/7/19 NE 236-238.

197 DBD at p 12.

Version No 1: 27 Oct 2020 (22:41 hrs)

Plaintiff at 1730 hrs cannot be faulted. The crucial point was that her clinical condition had improved from that taken at 1655 hrs.

161 Lastly, the Plaintiff cited the case of *Chia Foong Lin v Singapore Medical Council* [2017] 5 SLR 334 ("*Chia Foong Lin*") and two medical authorities (a textbook by Majid Samii,[198] and an article by Briggs and Kaye[199]) to argue that a CT scan was necessary at 1730 hrs in view of the worsening deficit from 1510 hrs.

162 Dealing first with the medical literature, the Plaintiff relied on the Samii textbook for the proposition that "Patients with a prolonged awakening phase, those who remain drowsy, or show progressive deterioration in their level of consciousness or worsening neurological deficit should undergo immediate CT scanning". The Briggs and Kaye article was cited for the proposition that "If the patient does not recover promptly from anaesthesia, or there is an unexpected significant neurologic deficit or a delayed neurological deterioration, a CT scan is done immediately to look for a cerebellar hematoma or infarction". The Plaintiff's point was that these authorities counselled against the "wait-and-see" approach that the Defendants' experts advocated. As the Plaintiff's counsel repeatedly emphasised, one must have regard to the "nature of the beast" – the beast being post-operative haemorrhage, and the nature being gradual deterioration followed by rapid decline. Without following the advice of such literature, a surgeon would fall into the fallacy of the situation always being too early to send a patient for a scan, until it is too late to intervene. It was not

198 PW5 Dr Tang's AEIC at p 140.

199 PW5 Dr Tang's AEIC at p 823.

Version No 1: 27 Oct 2020 (22:41 hrs)

hindsight reasoning, but rather, what eventually transpired validating in hindsight which was forewarned.

163 DW3 Dr Hong, when brought to the Samii textbook, agreed with the general proposition that if there is a worsening neurological deficit in the form of a drop in limb power a CT scan could be warranted despite the good GCS score. However, he said that as a clinician he would have to look at the general picture. If the patient were wide awake and talking to him, he would not send the patient for a scan even if the patient were hemiplegic. In that connection, it bears mentioning again that the Plaintiff had a GCS of 15 at 1730 hrs and was assessed to be alert. DW3 Dr Hong opined that if he followed the recommendation in the Sammi textbook he would be scanning every patient, but that would be following a recipe rather than being a clinician.[200] While his view did not conform with the Samii textbook, clinical judgment in practice was not "black and white".[201] His views were similar in relation to the Briggs and Kaye article. Similarly, DW4 Dr Ivan Ng emphasised that rigidly following the Samii textbook would mean the clinical practice was to do a CT scan for every single patient on a periodic basis.[202] He also did not accept that the Samii textbook applied in the same way in all situations, in particular, where hemiparesis was fluctuating.[203] DW4 Dr Ivan Ng was not referred to the Briggs and Kaye article.

---

200 8/7/19 NE 163-164.

201 8/7/19 NE 179.

202 11/7/19 NE 43.

203 11/7/19 NE 33.

Version No 1: 27 Oct 2020 (22:41 hrs)

164 I accept the logic of DW3 Dr Hong's and DW4 Dr Ivan Ng's explanation, notwithstanding the literature to the contrary. The exercise of clinical judgment entails making a decision on the facts, having regard to what the medical literature calls for. This cannot be as simple as following a formula or ticking boxes – otherwise there would be no need for trained doctors. DW3 Dr Hong candidly accepted that sometimes things could go downhill extremely quickly and a doctor might miss the chance for intervention.[204] But that must be the upshot of exercising clinical judgment because doctors are not infallible. If a doctor decides to exercise clinical judgment after taking into consideration the Plaintiff's condition, he cannot be easily faulted for not following the formulae of textbook writers, which are, in the final analysis, generalities, simply because the outcome happens to go awry. What is important is that DW3 Dr Hong and DW4 Dr Ivan Ng had explained their *reasons* for departing from textbook guidelines. If these reasons are logical and persuasive, their approach would have satisfied the *Bolam-Bolitho* standard.

165 Turning to *Chia Foong Lin*, in that case a doctor appealed against her conviction by a disciplinary tribunal ("DT") and her three-month suspension. The doctor had failed to diagnose a patient, a one-year-old boy, with Kawasaki Disease ("KD"), during either his hospital admission period of about a week or a clinic review two days after the discharge (which the court referred to as the "relevant period"). The doctor had persisted in her diagnosis of viral fever notwithstanding that the patient was showing some (but not all) symptoms of KD, in spite of the fact that a patient could also be diagnosed with the incomplete variant of KD ("Incomplete KD") if the complete features of KD

---

204 8/7/19 NE 186-187.

Version No 1: 27 Oct 2020 (22:41 hrs)

were not shown. The Plaintiff relied on [62] of *Chia Foong Lin*, where the court stated:

> It may be argued that because KD tends to mimic characteristics of other sicknesses (such as viral fever), Dr Chia's failure to identify Incomplete KD as a possible diagnosis and to order supportive tests to rule it out could be construed as a mere error in judgment as opposed to gross negligence. While we accept that such a view could be taken as of 28 February, or even 1 March 2013, this could not be so as of 3 March 2013 when the Patient visited Dr Chia at her Clinic with red lips and having had fever for the past two nights. *When the available tests to exclude KD are simple to undertake and when the consequences of no timely treatment of KD could be severe, it is not for a doctor to take chances with the well-being of a patient. If there was a need to take chances*, that determination should be left for the patient (or his parents if the patient is an infant) to make on an informed basis. We struggle to understand why such exclusionary tests, which were not harmful to the Patient, were not undertaken, or why the parents of the Patient were not informed of their availability. It is here that Dr Chia badly faltered. [emphasis added]

The Plaintiff argued that, similarly, a CT scan was simple to undertake and the consequence of failing to diagnose an extra-axial haematoma could be severe. However, *Chia Foong Lin* is distinguishable. The DT had rejected the evidence of the doctor's expert, Assoc Prof Quek, because his views were "more sympathetic and charitable". The court, in affirming the DT's decision, explained that Assoc Prof Quek's views on the standard of care and on the doctor's conduct were not sufficiently stringent (at [55]). In other words, the doctor's expert failed the test of logic in the *Bolitho* addendum. That is not the case for the Defendants' experts, DW3 Dr Hong and DW4 Dr Ivan Ng, in relation to the issue of whether a CT scan should have been ordered at 1730 hrs.

166 Accordingly, the Second Defendant was not negligent in not ordering a CT scan at 1730 hrs. The facts here resemble those of *Bolitho* in that there was a pattern of deterioration followed by recovery (albeit this happened twice in

Version No 1: 27 Oct 2020 (22:41 hrs)

Bolitho and once in the Plaintiff's case) before the ultimate catastrophic decline. The reasoning in *Bolitho* (reproduced at [104] above) applies equally to the question of whether a wait-and-see approach of close monitoring was reasonable and logical at 1730 hrs. The Defendants' experts considered that a CT scan at that time would have been unnecessary and I accept that view.

Interpretation of the First CT Scan

Introduction and overview

167 To recapitulate, following the developments up until 1730 hrs as discussed above, the Plaintiff's condition deteriorated further at 1805 hrs and 1820 hrs. At 1805 hrs her GCS dropped to 12 and her right limb power had dropped to 0/0. At 1820 hrs her GCS dropped to 10 and her right limb power remained at 0/0. The MPNs recorded her at 1820 hrs as having "R-sided weakness … GCS E3V1M6 pupils 2/2mm reactive … Labor[ed] breathing". This precipitated the First CT Scan at 1829 hrs.

168 The diagram below illustrates the key changes in the Plaintiff's GCS and neurological parameters over about four hours after she came out of surgery. The orange double-headed arrow denotes a GCS reading of 6 taken sometime while the Plaintiff was in the HDU. The exact timing is unclear.

Version No 1: 27 Oct 2020 (22:41 hrs)

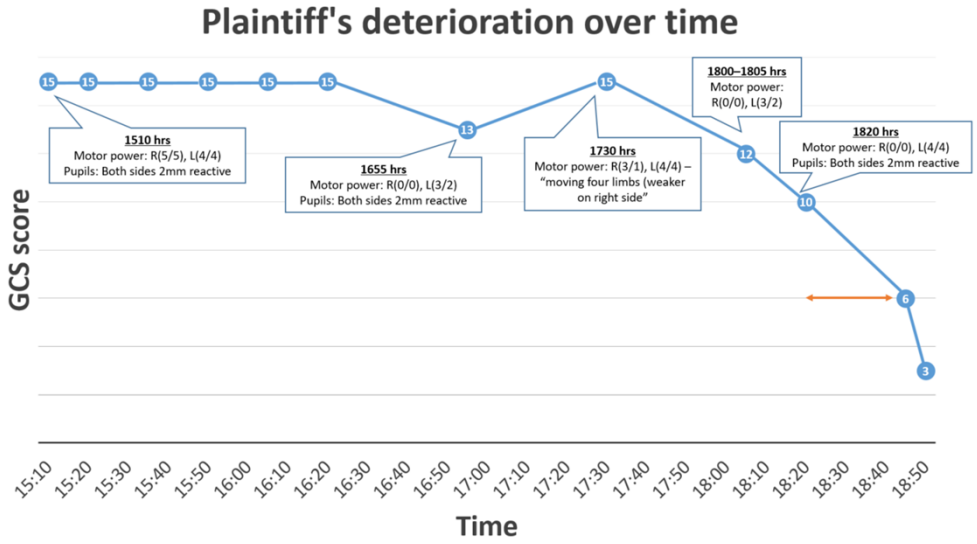

169 Before outlining the areas of disagreement, I digress briefly to explain the terminology that will be used in this part of the judgment. The terms "axial", "coronal" and "sagittal" refer to the three different planes from which a brain may be imaged using scanning technology such as MRI and CT, as seen from this diagram:[205]

[205] Diagrams referred to in AGMT, diagram 19.

Version No 1: 27 Oct 2020 (22:41 hrs)

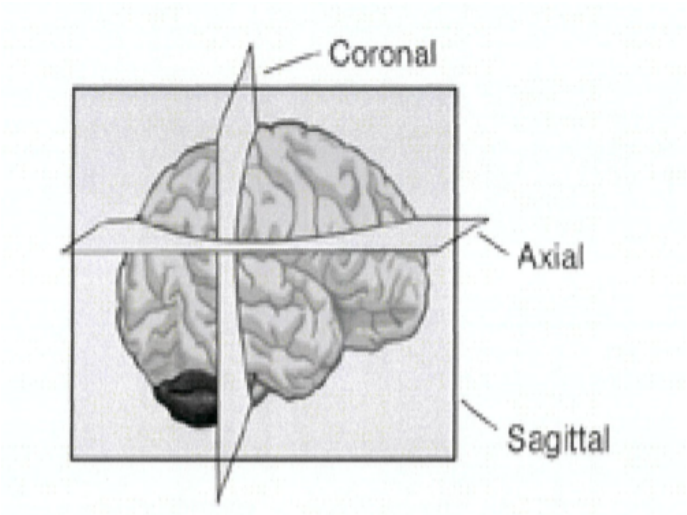

170 There were some disputes amongst the experts about whether the view of certain planes on the CT scan were more helpful than others in diagnosing the problem. The First Defendant's view was that the coronal images were the ones that clinched the diagnosis of intra-axial haematoma.[206] In contrast, PW4 Dr Pay and PW2 Dr Chua relied mainly on axial images, while DW3 Dr Hong's view was that it would be difficult to use the coronal images because of the way the brainstem slants obliquely.[207] PW4 Dr Pay also said at one point, after confirming that there was no comparison of images using the coronal slices, that "[i]t's not easy for me to use coronal to convince you of my points … but it is very helpful in the reading of the scan".[208] Ultimately, however, it was not seriously disputed that the diagnosis should be arrived at by considering all the planes (coronal, sagittal, or axial as illustrated in the diagram above at [169]).

---

206 14/5/19 NE 31.

207 9/7/19 NE 59.

208 2/5/19 NE 138–139.

Version No 1: 27 Oct 2020 (22:41 hrs)

For instance, PW3 Dr Gan and DW16 Dr Yu agreed that it would make for a more accurate interpretation if a doctor studies all different planes.[209]

171 It would also be useful to illustrate diagrammatically[210] the relevant structures of the normal brain, to which I shall refer in due course.

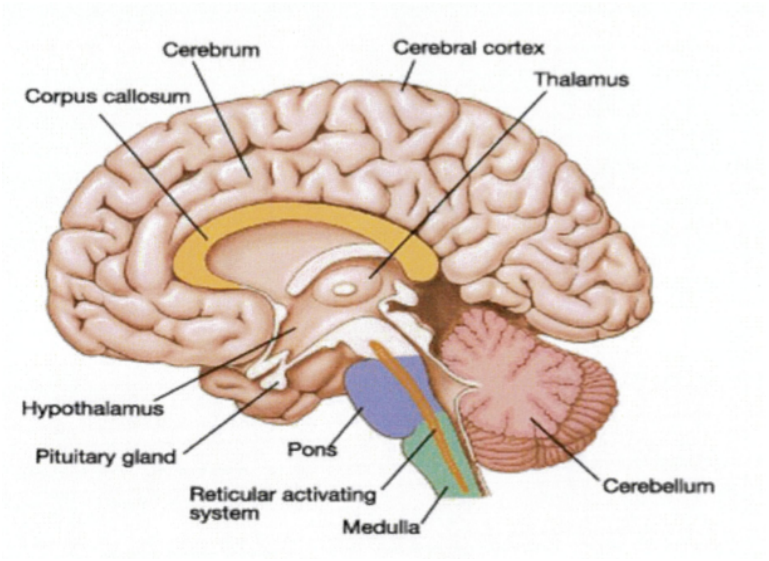

209 25/4/19 NE 151-154.

210 Diagrams referred to in AGMT, diagram 4.

Version No 1: 27 Oct 2020 (22:41 hrs)

The crux of the disagreement regarding the interpretation of the First CT Scan focuses on the circular-shaped haematoma located around the centre of the images below (corresponding to the location where the tumour used to be and which I shall refer to as "the tumour cavity"). The image on the left below is an axial cut of the First CT Scan and the image on the right is a coronal cut. It is also not disputed that the First CT Scan also shows haematoma in the surgical tract, which is by definition extra-axial. This appears as an oblong bright area on the axial cut and as an irregularly shaped patch on the coronal cut.

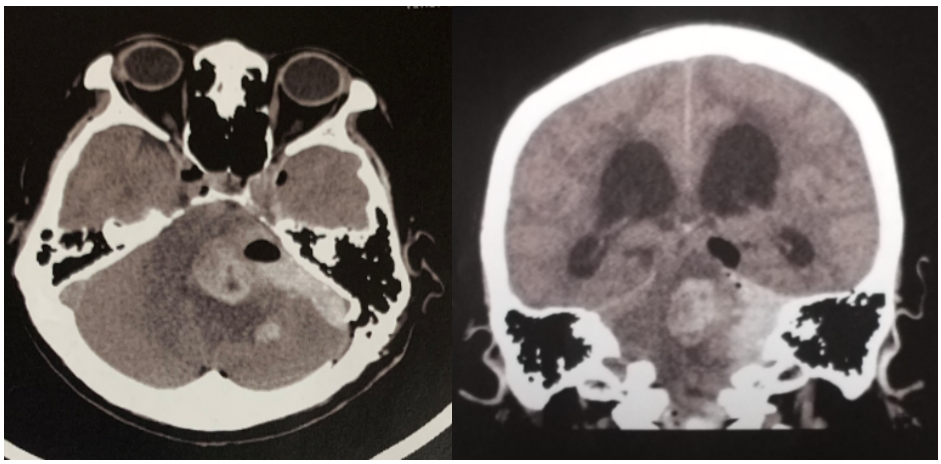

Axial (left) and coronal (right) views from the First CT Scan.

172 The parties do not dispute that the tumour cavity in the First CT Scan contains haematoma. The bone of strong contention regarding the haematoma in the tumour cavity is whether it is: (i) an *extra-axial* haematoma, in the sense that it existed in the free space in the brain that was not within the brain tissue, as the Plaintiff argues; or (ii) a significant *intra-axial* haematoma in the pons,[211] as the First Defendant contends.

---

211 Dr Yeo's AEIC at para 48.

Version No 1: 27 Oct 2020 (22:41 hrs)

173 I shall proceed to address the issue about the haematoma in the tumour cavity as follows:

(a) Firstly, I shall summarise the experts' evidence.

(b) Next, I shall discuss the key factors relied on by the experts in determining whether the haematoma in the tumour cavity was intra-axial or extra-axial. These fall into three groups:

(i) the location of the Plaintiff's pons after the First Surgery;

(ii) the Plaintiff's clinical presentation just before the Second Surgery; and

(iii) radiological features visible on the First CT Scan.

174 The first factor at [173(b)(i)] above warrants some explanation. Whether and to what extent the Plaintiff's pons rebounded is critical to the interpretation of the First CT Scan, as the surgeons and experts relied on the location of the pons as a vital landmark to assess whether the haematoma was extra-axial or intra-axial. Prolonged compression by the growing tumour had distorted the shape, size and location of the pons significantly compared to its normal position. The removal of the tumour freed up space previously occupied by the tumour – the tumour cavity. The dispute boils down to this:

(a) If the pons had rebounded to occupy part of the space in the tumour cavity, the First Defendant would be correct in saying that the haematoma in the tumour cavity was at least partially intra-axial haematoma in the pons. In this connection, PW2 Dr Chua accepted that

Version No 1: 27 Oct 2020 (22:41 hrs)

if his assumption that the brainstem remained displaced were wrong, his opinion that the haematoma was extra-axial would also be wrong.[212]

(b) If the pons had not rebounded, the Plaintiff would be right in saying the haematoma was extra-axial.

Therefore*, logic dictates that the issue of whether the pons rebounded must be resolved first* in discussing the three factors mentioned above, to avoid circular reasoning. I shall explain this in greater detail below (from [190]).

175 With that in mind, I shall now summarise the experts' evidence.

The experts' opinions

176 I begin with two preliminary observations.

(a) Firstly, for the reading of the scan, the Plaintiff's experts were radiologists, while the Defendants' experts were neuro-radiologists. A neuro-radiologist specialises in interpreting CT scans and MRI images of the brain and the spinal column. On the other hand, a radiologist looks at CT scans and MRI images of every organ or structure of the human body including the brain and spinal column. In other words, a neuro-radiologist is a sub-specialist while a radiologist is a generalist in radiology. Although PW2 Dr Chua had stated that there is no such thing as a neuroradiology sub-specialty or accreditation,[213] formal accreditation or the lack thereof would not change the *reality*, which is that neuro-radiologists read CT scans of the brain more frequently. PW4

212 24/4/19 NE 130-131.

213 2/5/19 NE 1.

Version No 1: 27 Oct 2020 (22:41 hrs)

Dr Pay accepted that he being a radiologist had no sub-specialty training in neurology. He acknowledged that a neuro-radiologists would be in a better position than him to comment on a CT brain scan. Neuro-radiologists would, therefore, be more familiar with the anatomy of the brain that concerns this court. PW2 Dr Chua and PW4 Dr Pay, the Plaintiff's experts, agreed in court that a neuro-radiologist would have more expertise and would better interpret the CT brain scan than a radiologist[214]. They were general radiologists while DW10 Dr Yeh and DW16 Dr Yu, the Defendants' experts, were neuro-radiologists. The court, therefore, has to be careful with the evidence of PW2 Dr Chua and PW4 Dr Pay, especially with regard to their views regarding the rebound of the pons into the tumour cavity after the First Surgery.

(b) Secondly, both sides contended at various junctures (when it suited their purposes) that the other side's experts were unsupported by medical literature, in a classic situation of the pot calling the kettle black. In any case, I did not find this decisive. The experts were entitled to also rely on their clinical experience and I assessed whether the views were well-founded on the *Bolam-Bolitho* standard having regard to their opinion *as a whole*. What is important is that an expert cannot merely present his conclusion without also presenting the underlying logic, reasons and the analytical process by which the conclusion was reached: *Lim Lian Arn* at [43].

177 Turning to the expert evidence proper, the Plaintiff's and Defendants' neurosurgeons, radiologists and neuro-radiologists had diametrically different

---

214 24/4/19 NE 118 lines 21-25; 2/5/19 NE 97 lines 7-9.

Version No 1: 27 Oct 2020 (22:41 hrs)

opinions on whether the haematoma in the tumour cavity was intra-axial or extra-axial. Generally, the Plaintiff's experts, except for PW3 Dr Gan who at one point accepted that the haematoma in the tumour cavity could be five to ten percent intra-axial and that there would be some brainstem recovery after the surgery into the tumour cavity, opined that the haematoma in the tumour cavity was extra-axial. On the other hand, the Defendants' experts asserted that there was significant intra-axial pontine haematoma as well as extra-axial haematoma. As I have explained (at [174]), this divergence of opinions results from their respective assumptions regarding the location of the pons, *ie*, whether the pons had not rebounded (Plaintiff's experts' views), or rebounded substantially or partially to occupy the space in the tumour cavity (as the Defendants' experts contended). Most of the experts drew on the hard copies of the CT scans where they thought the pons was, in the images below.

178 For comparison, I reproduce the First Defendant's annotations here. He was of the view that the haematoma in the tumour cavity was intra-axial pontine haematoma as the pons had rebounded into the tumour cavity after the First Surgery. He drew the blue outline representing the pons in the tumour cavity in the axial image below.

Clean image	**Annotated image**
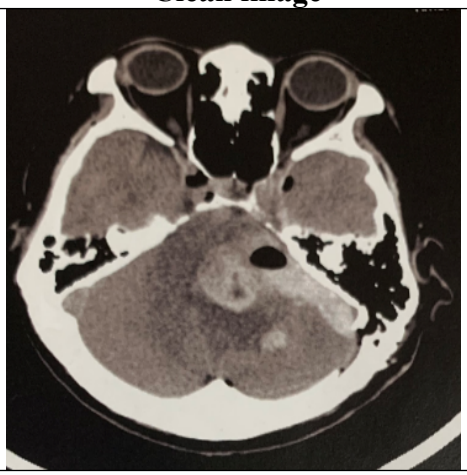	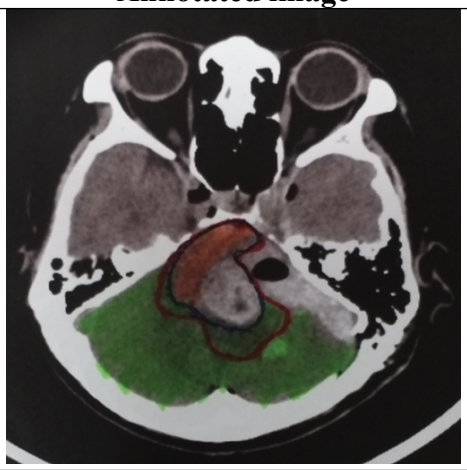

Version No 1: 27 Oct 2020 (22:41 hrs)

Axial view from the First CT Scan. Blue outline represents the pons. Red outline represents oedema. Orange shading represents oedema in the pons.

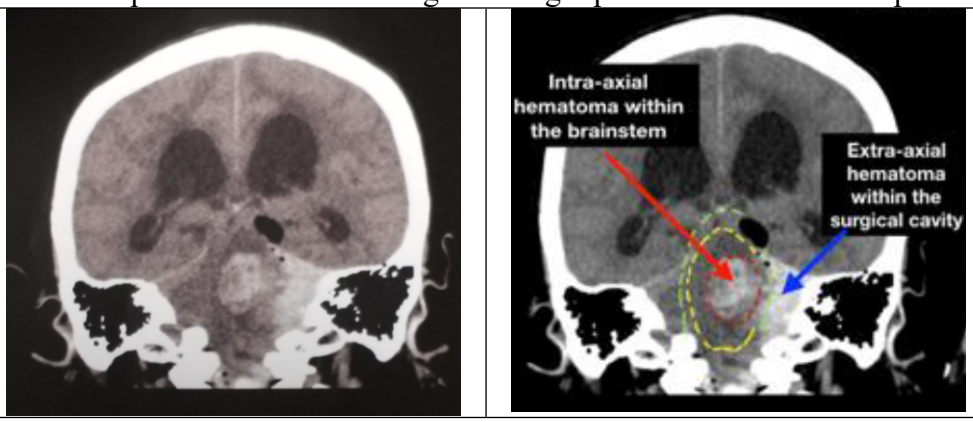

Coronal view from the First CT Scan. Green outline represents the brainstem.

(1) Plaintiff's experts

179 PW5 Dr Tang explained that the haematoma in the tumour cavity was entirely extra-axial.[215] He thought that the pons had not substantially rebounded. He also relied on the Plaintiff's clinical presentation. If the haematoma were intra-axial the Plaintiff would be paralysed on both sides and comatose, but that was not the case.[216]

Clean image	**Annotated image**

[215] 7/5/19 NE 26-35; PBD5 slide 8.

[216] 7/5/19 NE 54-65.

Version No 1: 27 Oct 2020 (22:41 hrs)

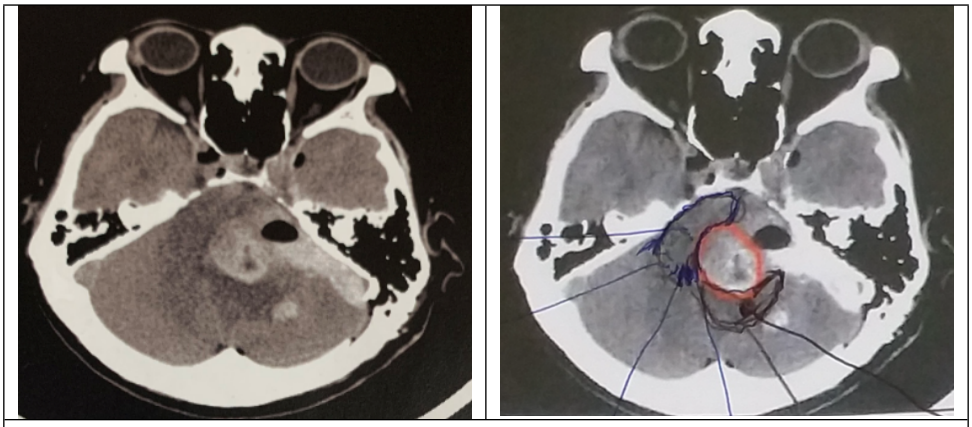

Axial view from the First CT Scan. Blue outline represents the pons.

180 It is not entirely clear what PW3 Dr Gan's view is. During cross examination by the Second Defendant's counsel, he opined that the bulk of the haematoma in the tumour cavity was extra-axial, with only about five to ten percent being intra-axial:[217]

> Q: You said the majority of the blood is extra-axial in the tumour bed. Do you recall saying those words?
>
> A: Yes, I did.
>
> Q: When you say "majority of the blood is extra-axial", can I ask you where is the rest of the blood?
>
> A: That is about 5 to 10 per cent intra-axial.
>
> Q: So you would estimate it to be 5--
>
> A: To 10 per cent.
>
> Q: Represented by what?
>
> A: The area of -- I mean, represented by the area of the blood clot.
>
> Q: So part of the blood clot we see you accept is intra-axial but the majority of it is extra-axial?
>
> A: That's correct.

[217] 26/4/19 NE 145.

Version No 1: 27 Oct 2020 (22:41 hrs)

However, during cross-examination by the First Defendant's counsel, he agreed with PW4 Dr Pay that the haematoma was wholly extra-axial:[218]

> Q: … Would I be correct that insofar as the radiological evidence is concerned you relied on Dr Pay's radiological reporting to come to your view as you have expressed in your first expert report that the haematoma seen in the 1829 CT scan was wholly extra-axial?
>
> A: I did say I also looked at Dr Alvin Hong's scans as well, which is in his report. So it's not just his.
>
> Q: Did you accept Dr Pay's radiological findings or his conclusion about the 1829 hours -- of the CT scan done on 2 June 2014 to be fully correct?
>
> …
>
> A: As it has been reported by him and he's a specialist, I would have to accept what he reported.

181 Unfortunately, PW3 Dr Gan was not asked to draw where he thought the pons was. In examination-in-chief he was asked about the possibility of the pons rebounding to its *original* position:[219]

> Q: There is also this point made by Dr Yeo through his lawyers that after the surgery the brain stem would have bounced back into its original shape. Do you have any opinion from your experience as to the likelihood of a brain stem that has been herniated due to a large tumour bouncing back when the tumour is excised?
>
> A: It is unlikely in all probability that the brain stem would move back to its original place. The reasons for saying so is, one, that tumour was a slow growing tumour and it is growing slowly to push the brain stem to one side; two, if you look at the brain of the patient, she has a brain that is actually relatively old, she has cerebral atrophy on top, which suggests that the compliance of the brain would not be as for someone that would bounce -- the brain stem would then bounce back. Three, I have personally not seen a brain bounce back

---

218 25/4/19 NE 154.

219 25/4/19 NE 53–54.

Version No 1: 27 Oct 2020 (22:41 hrs)

> that quickly, within two or three hours after surgery, and that's doing about 6,000 surgeries. So it's unlikely.
>
> Q: Does the MRI of 2 July give any assistance on this question of whether the brain stem had bounced back to its original shape?
>
> A: The MRI scan, still on the right-hand side was not back in the original shape, no.

In cross-examination, PW3 Dr Gan clarified that there would be some brainstem recovery but that it would take a lot more time for the brainstem to go back to its normal position:[220]

> Q: I just wanted to make sure I understood your evidence correctly, because you were asked if the pons would have recovered its shape after the removal of the tumour. Am I right in understanding your evidence to be that in principle you do not dispute the fact that the brain stem can start to recover its shape but you had doubts about the extent to which it would have happened in an older patient like Mdm Goh? Is that the gist of what you were trying to say?
>
> A.: Yes. Experience from operating in that area, there will be some brain stem recovery but it takes a lot more time for it to go back to normal.
>
> Q: In other words, it may vary from patient to patient; correct?
>
> A: Yes. Generally the younger you are, the faster it does -- the older you are, the less.
>
> Q: Would it be fair to say that this is something that the surgeons who were present would be in a better position to have seen and known about in this particular patient?
>
> A: When they were doing surgery, they would have obviously seen it, yes.
>
> Q: So they are in a more advantageous position; correct?
>
> A: Correct.

---

220 26/4/19 NE 117-118.

Version No 1: 27 Oct 2020 (22:41 hrs)

182 Both PW5 Dr Tang and PW3 Dr Gan appeared to routinely rely on radiologists to interpret scans, which undermines the confidence that this court may repose in their own interpretations. PW3 Dr Gan stated that he "[v]ery, very seldom" interprets scans without radiologist input, so much so that he stated he "can't remember a time that I don't refer to them".[221] PW5 Dr Tang, while stating that he was "reasonably comfortable" interpreting scans,[222] also stated that he relied on PW4 Dr Pay's reports in arriving at his opinion in the Plaintiff's case. To that extent the Plaintiff's case hinges strongly on PW4 Dr Pay's and PW2 Dr Chua's evidence.

183 PW4 Dr Pay explained that there was a single extra-axial haematoma at different stages of coagulation in the tumour cavity.[223] He said that the pons between the RadLink MRI and First CT Scan did not change significantly. In other words, PW4 Dr Pay opined that the pons did not rebound into the tumour cavity after the First Surgery. Hence, he drew the pons outside the tumour cavity as shown below and, therefore, concluded that the haematoma in the tumour cavity was entirely extra-axial.[224] PW4 Dr Pay also relied on the fact that the configuration of the haematoma conformed closely to that of the tumour.

Clean image	**Annotated image**

221 25/4/19 NE 141.

222 8/5/19 NE 22.

223 2/5/19 NE 63.

224 2/5/19 NE 126.

Version No 1: 27 Oct 2020 (22:41 hrs)

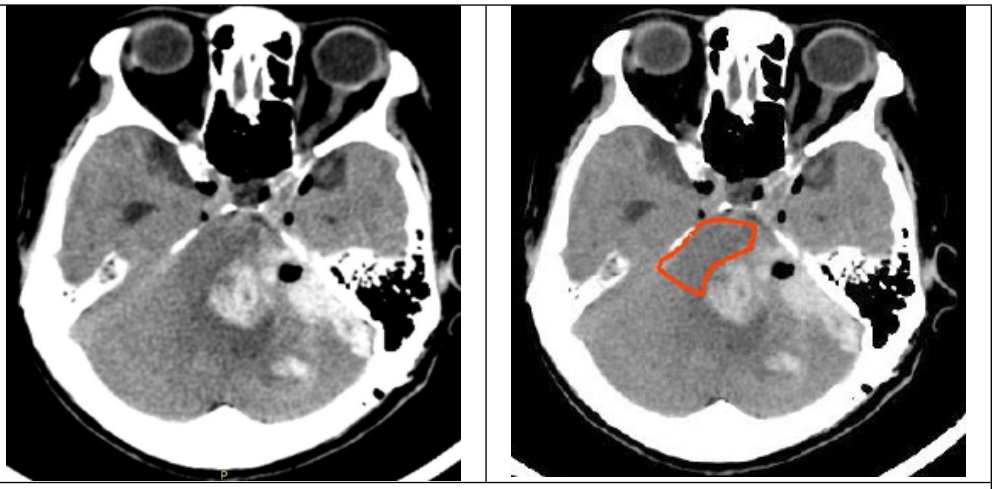

Axial view from the First CT Scan. Red outline represents the pons.

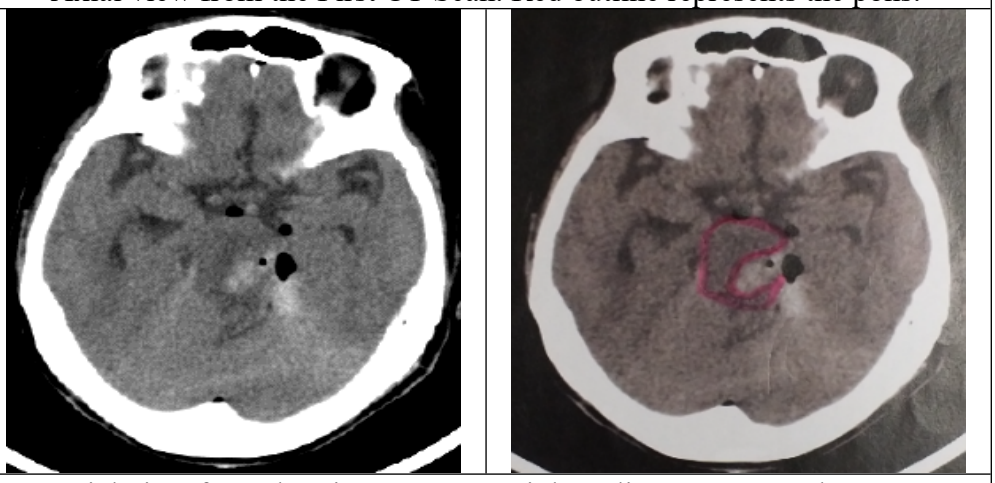

Axial view from the First CT Scan. Pink outline represents the pons.

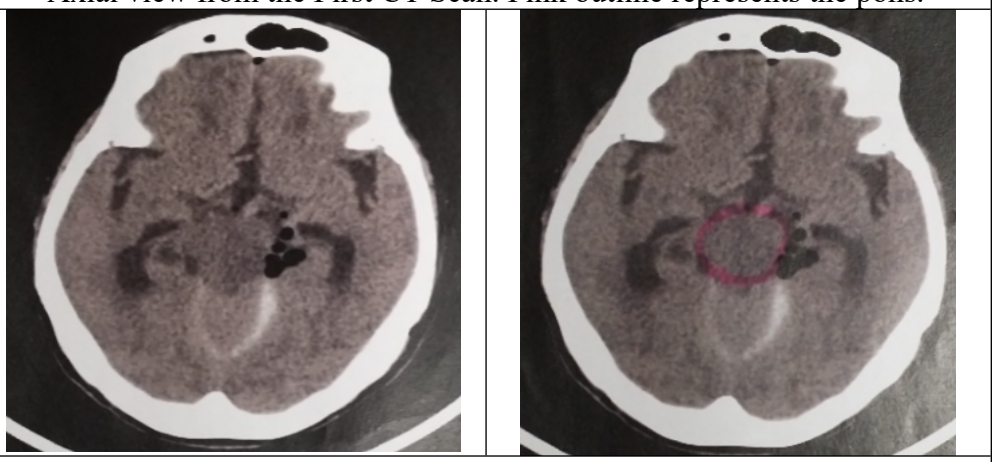

Axial view from the First CT Scan. Pink outline represents the pons.

Version No 1: 27 Oct 2020 (22:41 hrs)

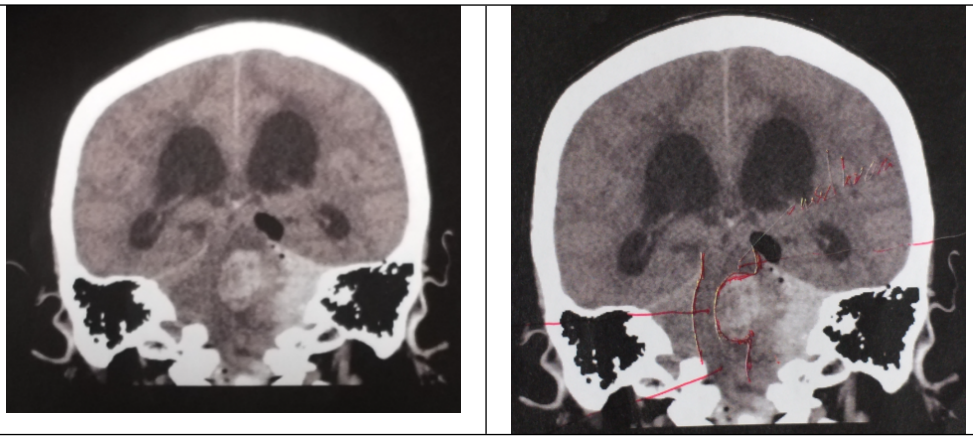

Coronal view from the First CT Scan. Middle portion of red outline represents the pons.

184 PW2 Dr Chua concluded that the tumour cavity showed an extra-axial haematoma, as he believed that the pons was still in the same location even one month after the operation (on an MRI dated 1 July 2014 ("the 1 July 2014 MRI")) although the MRI does not show the outline of the pons. He said that the extra-axial haematoma conformed to the shape of the tumour cavity. PW2 Dr Chua further explained that it was possible for the extra-axial haemorrhage to penetrate into the pons.[225] In relation to the bottom right image, I point out that there is an area of denser red shading (bounded by two thicker red lines) and an area of blue shading. PW2 Dr Chua had, in the course of giving evidence, over-shaded this portion and corrected himself later. He had initially not acknowledged that there was haematoma in the pons (contending that it was in the midbrain), but corrected himself.[226] I mention this to illustrate that the MRI scan cannot visibly indicate the pons, and that PW2 Dr Chua (like all the other experts) had to assume the location of the pons after the surgery.

Clean image	**Annotated image**

225 2/5/19 NE 13.

226 30/4/19 NE 174.

Version No 1: 27 Oct 2020 (22:41 hrs)

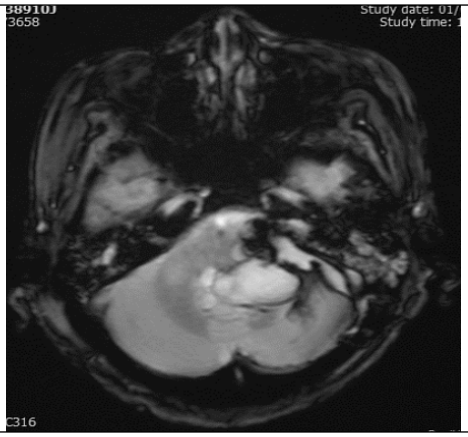

Axial view from the 1 July 2014 MRI scan. Dotted outline represents the pons.

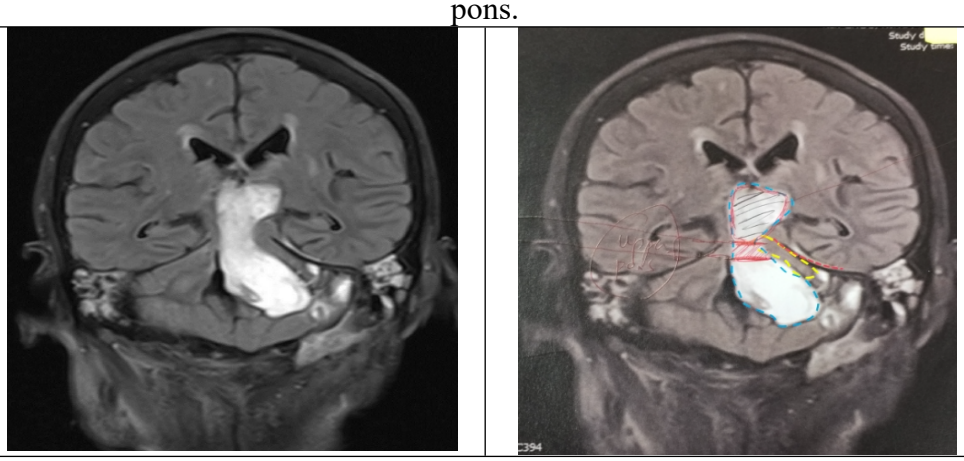

Coronal view from the 1 July 2014 MRI scan. Red shading represents the upper pons.

(2) Defendants' experts

185 DW4 Dr Ivan Ng opined that there was intra-axial haematoma in the pons and in the fourth ventricle.[227] His premise was that the Plaintiff's pons had rebounded and filled part of the tumour cavity, as seen from his annotation below.

Clean image	**Annotated image**

[227] 1D14 at slide 53.

Version No 1: 27 Oct 2020 (22:41 hrs)

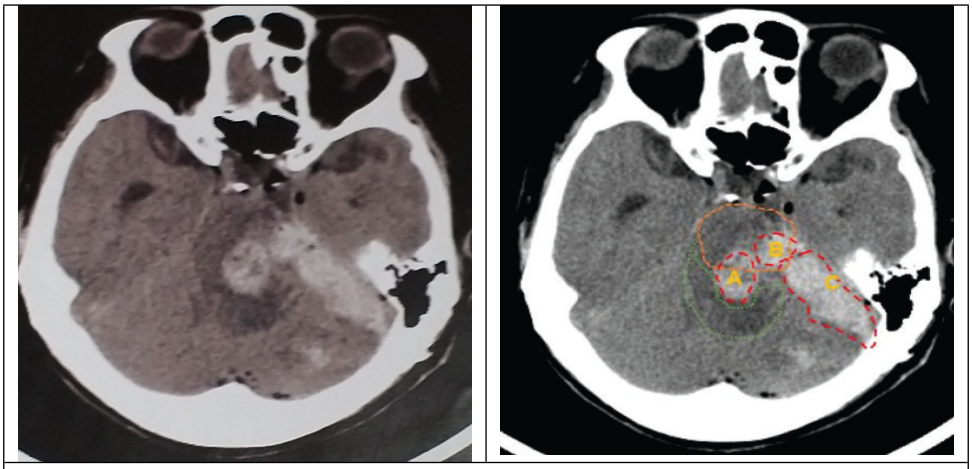

Axial view from the First CT Scan. Orange outline represents the pons.

186 DW10 Dr Yeh's view was that there was intra-axial haematoma in the pons, and in the left middle cerebellar peduncle ("MCP"), which was engorged with blood.[228] His premise was also that the Plaintiff's pons had rebounded and filled part of the tumour cavity. DW10 Dr Yeh's opinion was based on, amongst others, the differences in density within the haematoma, the position of air bubbles and the presence of a separating thin grey line.[229]

Clean image	**Annotated image**
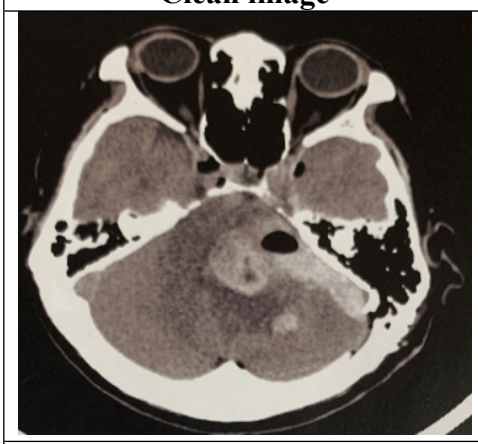	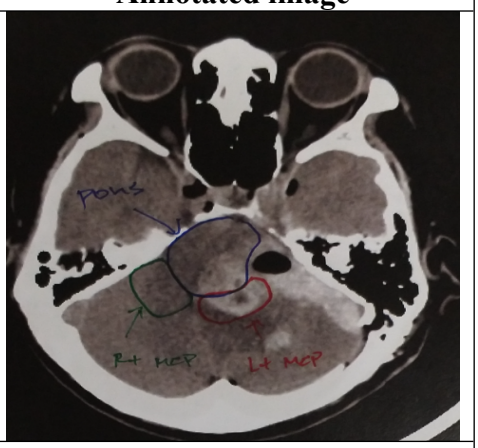

Axial view from the First CT Scan. Blue outline represents the pons.

228 17/7/19 NE 48; 1D16 at slide 19.

229 1D16 at slide 7.

Version No 1: 27 Oct 2020 (22:41 hrs)

187 DW10 Dr Yeh supported his diagnosis of the intra-axial haematoma in the tumour cavity with the subsequent progression of the haematoma, as seen from the 1 July MRI. Specifically, he focused on:

(a) the upward extension of the haematoma in a tubular fashion following the line of the pons, up to the junction with the midbrain (DW10 Dr Yeh identified a separate haematoma in the midbrain that was beginning to merge with the haematoma in the pons, which suggested that they both lay within the same tubular structure, this being the brainstem); and

(b) the different extents to which haemosiderin was present.[230] Haemosiderin is a product of red blood cell breakdown and is visible along the margins of a resolving haematoma. It is particularly visible on a type of image called a gradient recalled echo image.[231]

Factors (a) and (b) above are illustrated in the first and second rows of images below, respectively.

Clean image	**Annotated image**

[230] 1D14 at slides 39, 44.

[231] 1D16 at slide 44.

Version No 1: 27 Oct 2020 (22:41 hrs)

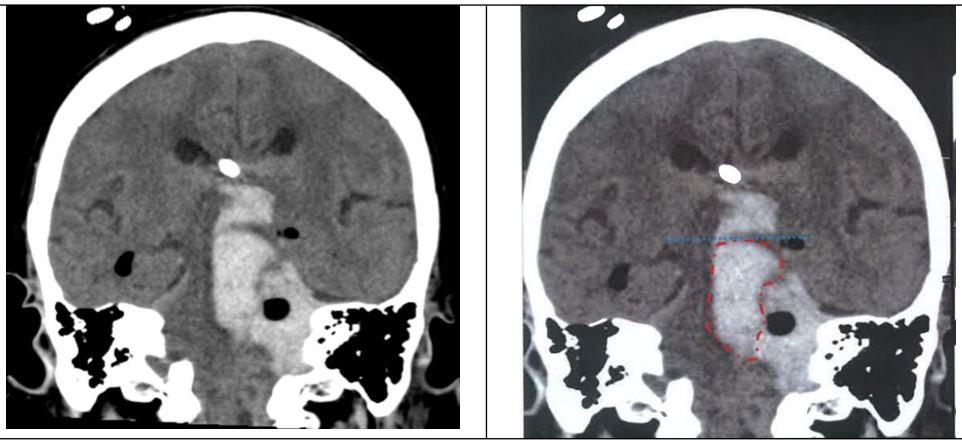

Coronal view from the CT Scan on 3 June 2014. Red outline represents pontine haematoma, blue outline represents junction with midbrain.

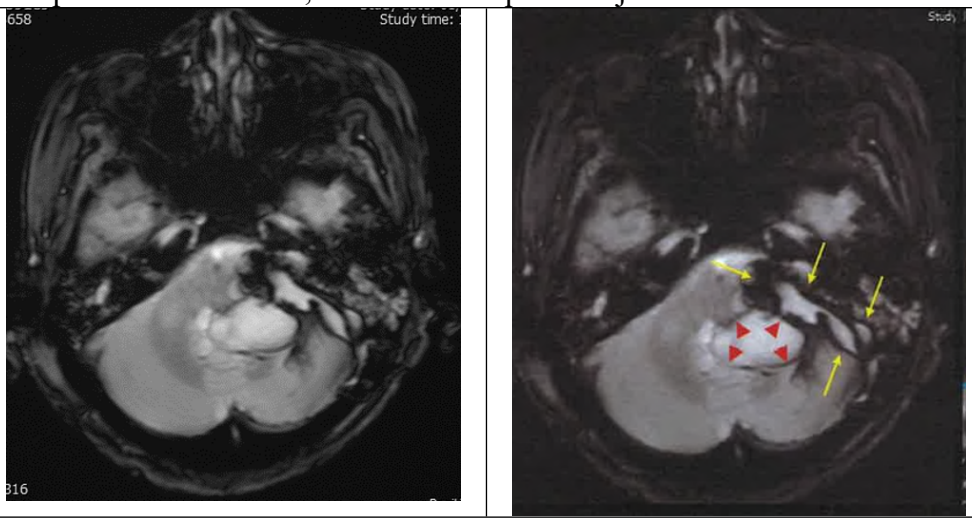

Axial view from the 1 July 2014 MRI scan. Yellow and red arrows indicate the different borders for extra- and intra-axial haematomas.

188 DW16 Dr Yu opined that the haematoma in the tumour cavity was both intra-axial and extra-axial.[232] While most of the haematoma there was extra-axial, there was an area with no clear plane (*ie*, a fuzzy border), which was suggestive of intra-axial haemorrhage of the haematoma into the pons because extra-axial haemorrhage would have a clear border where it abuts brain tissue.

---

232 2D6 at slides 3–4, 30; 5/8/19 NE 11-12, 30-31; 6/8/19 NE 8.

Version No 1: 27 Oct 2020 (22:41 hrs)

DW16 Dr Yu was uncertain as to the precise extent of intra-axial extension of the haematoma though she estimated this as a "small amount".[233] DW16 Dr Yu marked the region of the pons that was *unaffected*. However, she had difficulty in depicting the region of the pons that was affected by haematoma as the boundary of the affected pons was uncertain and fuzzy. DW16 Dr Yu disagreed with PW4 Dr Pay's annotation of the pons after the surgery and opined that this annotation represented only the normal portion of the pons (in contrast with her opinion that there was, additionally, a portion of the Plaintiff's pons that was affected by haematoma).[234]

Clean image	**Annotated image**
	
Axial view from the First CT Scan. Picture on the right is an enlarged image of the picture on the left. Red outline (not red dotted line) represents unaffected pons. Blue outline represents area of uncertainty with possible intra-axial extension of haematoma into the pons.	

233 6/8/19 NE 37.

234 6/8/19 NE 140.

Version No 1: 27 Oct 2020 (22:41 hrs)

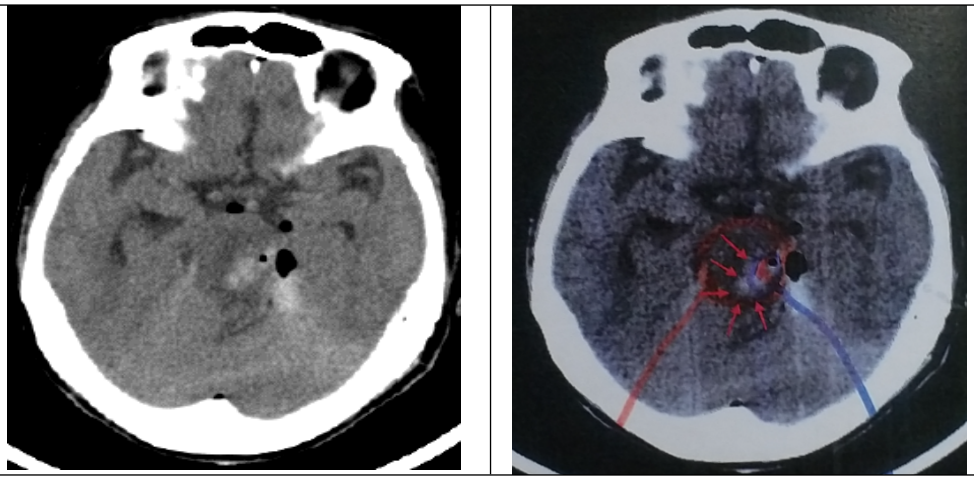

Axial view from the First CT Scan. Red outline represents the pons.

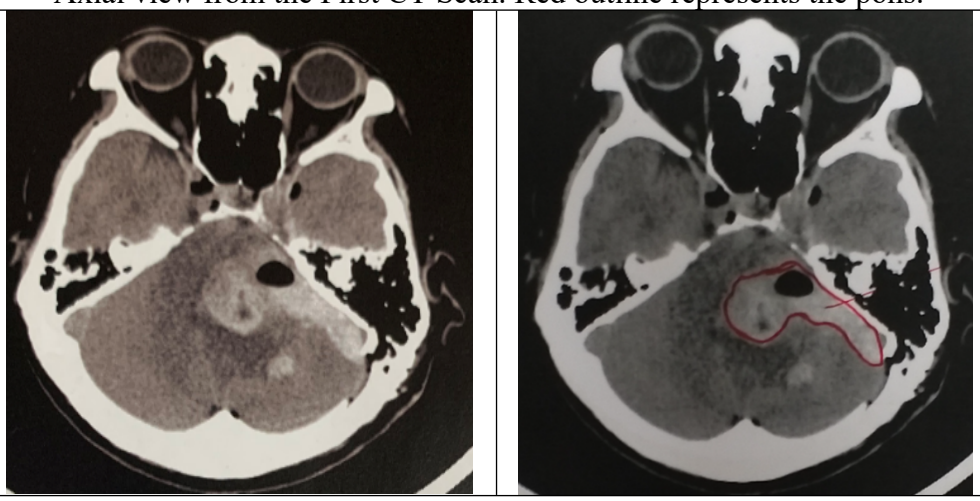

Axial view from the First CT Scan. Red outline represents extra-axial haemorrhage.

189 DW3 Dr Hong opined that the tumour cavity showed a small portion of intra-axial pontine haematoma in the brainstem. There was a larger haemorrhage which he concluded on balance to be extra-axial[235] (though he initially stated he could not determine whether this was intra-axial or extra-axial[236]). Crucial to his reasoning was that the two haematomas were

235 9/7/19 NE 53–54.

236 8/7/19 NE 52.

Version No 1: 27 Oct 2020 (22:41 hrs)

separated by greyish-looking brain tissue, which implied they were separate haematomas and not a single haematoma.[237] DW3 Dr Hong was not asked to draw the pons, though he explained that the brainstem had been squashed by a tumour and thus would invariably rebound by "a bit" once the tumour was removed.[238]

Clean image	**Annotated image**
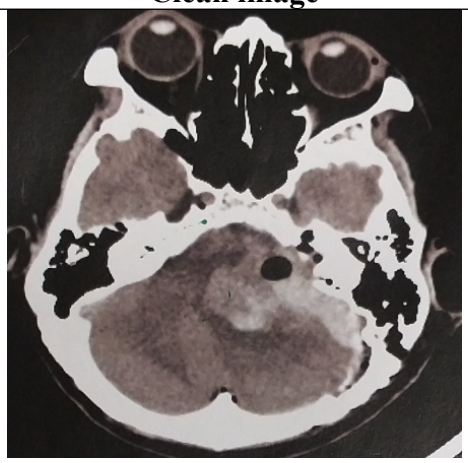	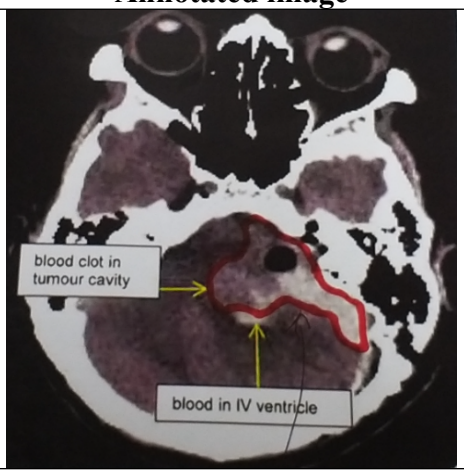
Axial view from the First CT Scan. Red outline represents blood in the tumour cavity.	

Discussion and findings

(1) The location of the Plaintiff's pons

190 As alluded to above at [174], the neurosurgeons and radiologists in this case faced significant difficulties in interpreting the First CT Scan. One of the common challenges faced by the neurosurgeons, radiologists and neuro-radiologists was that the CT scan images did not outline, distinctly or even faintly, the structure of the pons. What compounded their difficulty was that the pons and other structures in the Plaintiff's posterior cranial fossa that they would

237 8/7/19 NE 49.

238 9/7/19 NE 90.

Version No 1: 27 Oct 2020 (22:41 hrs)

have relied upon for their interpretation of the CT scan in normal circumstances were distorted by the tumour which had been removed after the First Surgery.

191 CT scans show up as portions of black, white and different shades of grey. Neurosurgeons and radiologists must have a good knowledge of where the different structures are located within the brain as these serve as vital "landmarks" to interpret scans, which to the untrained eye simply comprise different shades of grey – see, for instance, the illustrative images directly below of an unannotated image, and an annotated image by DW10 Dr Yeh of where the pons is in a normal person:[239]

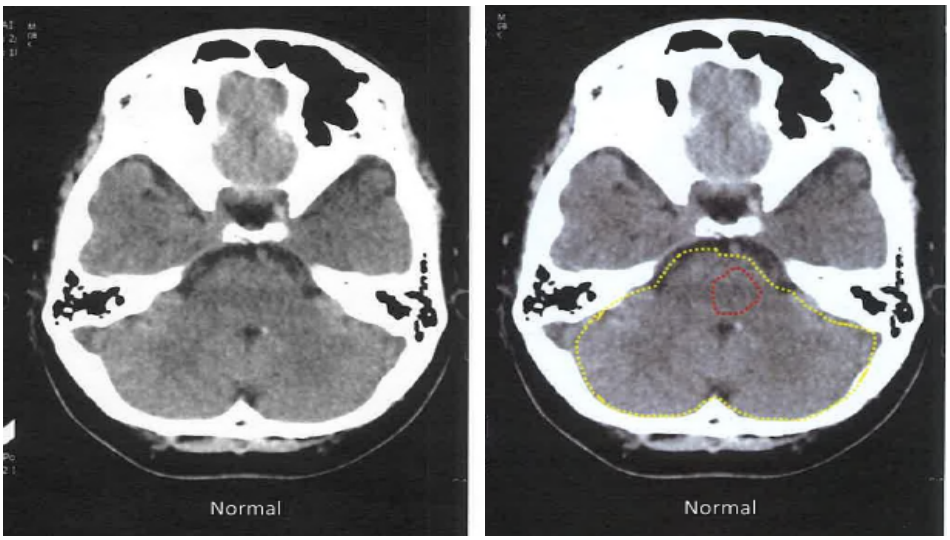

Axial views of normal brains.

192 The reason why experts can interpret and annotate scans is that *they base their interpretation on their knowledge of the anatomy of the brain*. This proposition about the necessity of using landmarks to interpret the CT scan is a vital methodology used by all the experts. But in the Plaintiff's case, the

[239] 1D16 at slides 20 and 22.

Version No 1: 27 Oct 2020 (22:41 hrs)

structures in her posterior cranial fossa – the cerebellum, fourth ventricle, pons, MCP *etc* – had been significantly distorted by the tumour over time. It would be difficult to interpret accurately whether the haematoma in the tumour cavity was intra-axial or extra-axial purely by reference to where one *would expect* the pons to be in a normal situation, without having regard to the changes effected by the tumour and the further changes that might have occurred after the tumour removal. The crucial structures that the neurosurgeons, radiologists and neuro-radiologists heavily relied on as landmarks to interpret the First CT Scan were distorted after the huge tumour had been removed.

193 The annotations of the experts for both sides, which I have set out above, bear out this difficulty. What they have delineated as the outline of the pons is often not visible on the scan itself. In other words, they drew their best guess of where they *inferred* the pons and other structures to be, based on their knowledge of the anatomy of the Plaintiff's posterior cranial fossa. DW4 Dr Ivan Ng and DW10 Dr Yeh candidly accepted that the outline of the pons was not visibly discernible from the First CT Scan and had to be superimposed on the scan.[240] In similar vein, the Plaintiff's experts, PW2 Dr Chua and PW4 Dr Pay, interpreted the First CT Scan on the assumption that the pons did not rebound into the tumour cavity. While this approach cannot be faulted if we were dealing with a normal brain, here the structures in the Plaintiff's posterior cranial fossa were distorted. It is this difficulty (*ie*, the fact that the location of the pons is based on each expert's inference) that led to their divergence of views over whether the haematoma in the tumour cavity was intra-axial or extra-axial.

---

240 11/7/19 NE 85; 17/7/19 NE 153.

Version No 1: 27 Oct 2020 (22:41 hrs)

194 The above explains the vast differences in the interpretation of the same CT scan by the Plaintiff's and Defendants' neurosurgeons, radiologists and neuro-radiologists. To summarise the witnesses' opinions on the position of the pons:

(a) Two of the Plaintiff's experts (PW2 Dr Chua and PW4 Dr Pay) opined that the displaced pons remained where it was even after the tumour removal. PW3 Dr Gan relied on PW4 Dr Pay's interpretation though, as I have mentioned, he also stated that the haematoma was 5–10% intra-axial which differed from PW4 Dr Pay's conclusion. PW5 Dr Tang considered that although there would be rebound, the shift was only a "slight, but not significant" shift that would not invalidate any comparison with the RadLink MRI.[241] This was their basis for interpreting the First CT Scan as showing that there was no pontine haemorrhage. It would be fair to summarise the Plaintiff's stance as generally, there being *no or very slight rebound* of the pons and to say that the Plaintiff's experts broadly supported this (PW3 Dr Gan said "slight recovery"[242], PW5 Dr Tang said "slight shift"[243] and PW4 Dr Pay and PW2 Dr Chua said the pons was in the same position as pre-operation).

(b) The Defendants' experts exhibited a range of opinions. The First Defendant went the furthest in drawing a pons that rebounded to fill almost the entire tumour cavity and hence encompassed the entire egg-shaped haematoma. Although none of his experts went that far, all of

241 8/5/19 NE 127.

242 26/4/19 NE 117-118.

243 8/5/19 NE 127.

Version No 1: 27 Oct 2020 (22:41 hrs)

them opined that there was at least *some* rebound. They differed on the precise extent.

195 The Plaintiff argues that the First Defendant's diagnosis was unsupportable simply because none of his factual or expert witnesses thought the pons had rebounded to the same degree that he believed or identified the same region of haematoma as intra-axial that he had. She alleges that even if, for instance, DW11 Dr Pang's evidence on rebound of the pons is accepted, DW11 Dr Pang drew a smaller pons than the First Defendant did.[244] This contrasts with the Plaintiff's experts, who opined that there was *no* pontine haematoma, except for PW3 Dr Gan who opined that there was 5–10% intra-axial haematoma and petechial haemorrhages in the brainstem.[245] The *Bolam-Bolitho* test does not require the court to rule on where exactly the boundaries of the pons are (and by extension, where the boundaries of the intra-axial haematoma are). Even the very experienced experts could not agree on this important issue. The court should not act as though it is knowledgeable in the field of neurosurgery, and is better-placed than all the experts combined to be able to decide whether to accept the Plaintiff's or the Defendants' version. Under the *Bolam-Bolitho* test, the critical issue is whether the First Defendant's view (*ie*, that there can be some rebound of the pons such that there is a "significant brainstem haematoma component in addition to an extra-axial blood clot"[246] in the tumour cavity) is logical and defensible. That is because even some rebound would mean the haematoma in the tumour cavity was partially intra-axial in the pons, and ***even a small haematoma in the pons can***

---

244 PRS at paras 82-83.

245 25/4/19 NE 129.

246 Dr Yeo's AEIC at para 48.

Version No 1: 27 Oct 2020 (22:41 hrs)

be significant because the pons is itself a small structure. This was the evidence of PW3 Dr Gan, the Plaintiff's expert, who said that "in the brain stem when it is very small, a small clot can give a big effect".[247] Similarly, the Defendants' expert who took the most conservative view (*ie*, that the pons had rebounded the least), DW3 Dr Hong, thought that having haematoma in the pons to that small degree still entailed a poor prognosis. In other words, the Defendants' experts opined that *any* rebounding of the pons into the tumour cavity indicated intra-axial or pontine haematoma. Though they diverged on the precise extent of rebound (hence the precise extent of intra-axial haemorrhage), they were *ad idem* on the Plaintiff's poor prognosis because even a small pontine haematoma was, in their view, serious. Thus, I do not accept that the First Defendant's view cannot be said to be supported by a body of logical and sensible expert opinions simply because his experts do not take precisely the same view of the *extent* of pons rebound or intra-axial haematoma. What is important is that they all agreed that the intra-axial haematoma, to the extent that they identified, was significant.

196 Having heard the views of the experts of the Plaintiff and the Defendants as well as their witnesses, I am inclined to accept that at 1829 hrs, the time of the First CT Scan, the pons had rebounded to fill *part* of the tumour cavity and this indicates that there was intra-axial (pontine) haematoma although there was also extra-axial haematoma.[248] I shall now explain my views.

197 Firstly, and most importantly, PW3 Dr Gan, the Plaintiff's expert neurosurgeon, accepted that the operating surgeon, *ie*, the First Defendant,

---

247 26/4/19 NE 104–105.

248 16/5/19 NE 185-186; 22/5/19 NE 55.

Version No 1: 27 Oct 2020 (22:41 hrs)

would be in a better position than he to know whether the Plaintiff's pons rebounded *because he would have seen this during surgery*.[249] PW4 Dr Pay, the Plaintiff's radiologist, similarly agreed that the First Defendant would be the best person to know how or whether the brain structures moved.[250] In this regard, DW11 Dr Pang, who assisted the First Defendant in the First Surgery, testified that he had actually seen the pons rebound during the First Surgery:[251]

> Court: When you removed the tumour, could you see the pons expanding?
>
> A: Yes, because at the end of the resection, you could see that as the pons came up towards you, the space has become smaller.

---

249 26/4/19 NE 118.

250 2/5/19 NE 101.

251 18/7/19 NE 5, 24-25.

Version No 1: 27 Oct 2020 (22:41 hrs)

198 DW11 Dr Pang added during his cross-examination that he could see the pons moving back at the end of the surgery, over a period of time anywhere between five to fifteen minutes as the retractors (*ie*, tools to pull back the cerebellum and other structures in the posterior cranial fossa to allow surgeons to access and remove the tumour) were removed.[252] DW11 Dr Pang annotated where he thought the pons was on an axial cut of the First CT Scan – he accepted that the pons was not visible from the CT scan but he based his annotation on his anatomical knowledge after the First Surgery[253] – and *also where he last* ***sighted*** *the pons before the surgical opening was closed*.[254]

Clean image	**Annotated image**
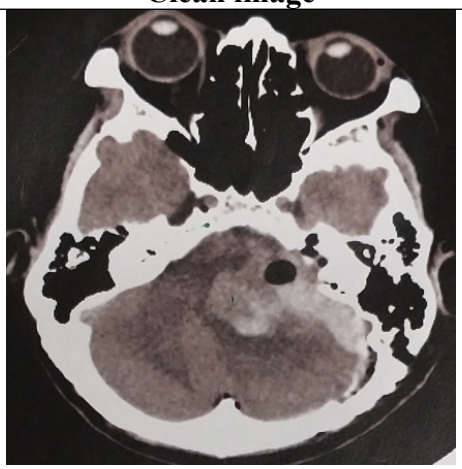	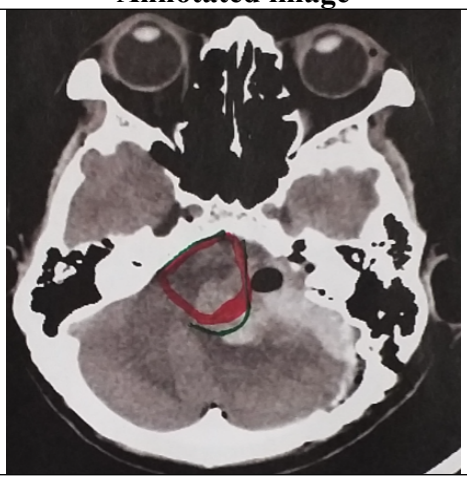

Axial view from the First CT Scan. Red outline represents the pons. Green line represents DW11 Dr Pang's visual sighting of the pons during the First Surgery.

DW11 Dr Pang explained that while seeing the pons rebound increased his certainty in interpreting the First CT Scan to conclude that the haematoma in

252 18/7/19 NE 84.

253 8/7/19 NE 141.

254 DBRI48A; 18/7/19 NE 90.

Version No 1: 27 Oct 2020 (22:41 hrs)

the tumour cavity was intra-axial, this did not mean he would not have come to the same view without seeing the movement of the pons. This observation had increased his confidence level that the Plaintiff's pons had rebounded.[255]

199 Although the Plaintiff raises four main criticisms with regard to DW11 Dr Pang's testimony,[256] I do not find these arguments to be persuasive.

(a) The Plaintiff contends that DW11 Dr Pang's testimony that he had personally witnessed the pons rebound was not in his affidavit of evidence-in-chief and should not be admitted under O 38 r 2(3) of the Rules of Court, which states:

> Unless the Court otherwise orders, no deponent to an affidavit may at the trial or hearing of any cause or matter give evidence-in chief, the substance of which is not contained in his affidavit except in relation to matters which have arisen after the filing of the affidavit.

However, that argument ignores O 38 r 2(4) of the Rules of Court, which entitles the court to order the giving of evidence notwithstanding O 38 r 2(3) as long as the oral evidence is an "amplification of the affidavit evidence and will not take the other party by surprise": *Singapore Civil Procedure* at para 38/2/4. This is the case here, as DW11 Dr Pang had referred in his affidavit to how the tumour cavity was "easily visualised" after the retractors were removed.[257] I shall elaborate on this issue below as the other experts also did not mention the rebound of the pons in their affidavits.

---

255 18/7/19 NE 137.

256 PCS at paras 155-160.

257 DW11 Dr Pang's AEIC at para 12.

Version No 1: 27 Oct 2020 (22:41 hrs)

(b) The Plaintiff contends that it was impossible for DW11 Dr Pang to observe the pons rebounding with both the microscope and the naked eye because the line of sight through the microscope was in the shape of a "dog leg", with no direct view into the pons, and was also "extremely limited and not a panoramic view". This was put to DW11 Dr Pang, who consistently disagreed that the pons was not visible in his line of sight. In my view, the surgeons in the removal of the tumour would initially not be able to see the pons as their views of the pons would have been obstructed by the huge tumour. However, after most of the tumour was removed they would have seen the pons and they had to be careful not to damage the pons. That explains why they had to leave behind a small remnant of the tumour capsule that was closely adhered to the pons. In fact, DW11 Dr Pang testified that the movement of the pons was something he paid close attention to because this would affect the positioning of his fingers and instruments during surgery.[258] DW11 Dr Pang also explained that the microscope would not provide a panoramic view if the magnification was highly zoomed in, but surgeons would not keep the microscope at maximum magnification throughout the surgery.[259]

(c) The Plaintiff contends that only the First Defendant and DW12 Dr Low actually had a three-dimensional view of the First Surgery, whereas DW11 Dr Pang only had a two-dimensional flat view of the surgical field.[260] The Plaintiff's point is that the omission by the First

---

258 18/7/19 NE 114-117.

259 18/7/19 NE 116.

260 PRS at para 80.

Version No 1: 27 Oct 2020 (22:41 hrs)

Defendant or DW12 Dr Low to testify about seeing the pons rebound is significant because the viewer would have a better appreciation of depth on a three-dimensional view. I do not accept this argument. The First Defendant and DW12 Dr Low were not specifically asked whether they had *seen* the pons rebound.

(d) Finally, the Plaintiff contends that DW11 Dr Pang was not a credible witness because he was inconsistent and blamed the drafting of the affidavit of evidence-in-chief. The Plaintiff also takes issue with how DW11 Dr Pang apparently sought to give the court the impression that he was an integral part of the surgical team when the First Defendant actually looked to DW12 Dr Low (not DW11 Dr Pang) as his main assistant.[261] DW11 Dr Pang's evidence was unwavering on the crucial aspects of whether he saw the pons rebound. I also did not find that DW11 Dr Pang came across as trying to inflate the importance of his role. DW12 Dr Low had testified that "there were instances where DW11 Dr Pang did take over [his] role as an assistant" when he left the operating field, given that surgical access was only possible for two pairs of hands within the field at one time.[262]

I, therefore, accept DW11 Dr Pang's evidence that he saw the pons rebounding at the close of the First Surgery.

200 Secondly, there is insufficient basis to conclude that the Plaintiff's pons could not rebound as it had atrophied as a result of the growing tumour compressing the pons. The experts' views on atrophy are as follows:

---

261 PCS at para 159; PRS at para 79.

262 18/7/19 NE 219–220.

Version No 1: 27 Oct 2020 (22:41 hrs)

(a) PW2 Dr Chua, the Plaintiff's expert radiologist, opined that the tumour pressing against the pons caused atrophy and adhesion. Thus it would take months for the pons to rebound.[263] However, he also accepted that he had not seen cell atrophy and had no first-hand experience of how the brain behaves.[264] As for the adhesion theory, this was not explained in any detail and was, as the First Defendant points out, not put to any of the Defence's experts.[265]

(b) DW11 Dr Pang stated in examination-in-chief that "[t]here probably is some atrophy, but it is far less than what most people think. Maybe 10, 20 per cent I can accept, but certainly not more than 50 per cent".[266] But that must be seen in context with the rest of his evidence, where he stated:[267]

> The MRI indeed does show the pons is a bit smaller because of the pressure effect from the tumour. *I would be very hesitant to use the word "atrophy" because atrophy implies there is irreversible damage to the structure which means it will never recover or never re-expand, and that is clearly not true.* In cases where the brain stem or any brain structure is slowly compressed by a tumour, relieving of the pressure often allows certain degree of re-expansion. That is because when a structure is compressed slowly, often what is displaced is the water content, and while there might be a small amount of damage, it is not inevitable that the whole structure will die off. And when the compression is released, the water is restored and there is some degree of re-expansion. [emphasis added]

---

263 24/4/19 NE 51; 2/5/19 NE 8.

264 30/4/19 NE 53.

265 D1CS at para 206.

266 18/7/19 NE 28.

267 18/7/19 NE 3-4.

Version No 1: 27 Oct 2020 (22:41 hrs)

(c) PW3 Dr Gan, the Plaintiff's expert neurosurgeon, opined that the Plaintiff was relatively old and had cerebral atrophy. Hence, it was less likely for the Plaintiff's brainstem to rebound.[268] He therefore said that the Plaintiff's pons had not returned to its original shape on 2 June 2014.[269] The Defendants are not suggesting that the pons had returned to its *original* shape and location after the tumour was removed. PW3 Dr Gan was also not asked to sketch what he thought was the location of the pons on the 1 July 2014 MRI.

201 Thirdly, I do not accept the view that it was premature for the Plaintiff's pons to rebound after the tumour was removed. DW4 Dr Ivan Ng, the Defendants' expert neurosurgeon, explained that the Plaintiff's pons could have rebounded almost fully within four hours after tumour removal, though he was careful to mention that there would be inter-individual variations.[270] PW3 Dr Gan, the Plaintiff's expert neurosurgeon, also agreed that there would be some recovery and the pons would have some rebound. However, he doubted that the brainstem could go back to its *normal* position within two to three hours after surgery.[271] But as DW10 Dr Yeh, the Defendants' expert neuro-radiologist, explained, the timeframe for the pons to begin rebounding was *not* two to three hours from the *end* of the First Surgery at 1415 hrs to the First CT Scan at 1829 hrs. He opined that that process of rebounding would have started from near the *beginning* of the First Surgery at about 1000 hrs, this being the time the surgeon

---

268 26/4/19 NE 117-118.

269 25/4/19 NE 54; 1D12.

270 10/7/19 NE 78-79, 82–83; 11/7/19 NE 12, 117.

271 25/4/19 NE 54; 26/4/19 NE 117.

Version No 1: 27 Oct 2020 (22:41 hrs)

first went in to relieve pressure in the posterior cranial fossa.[272] DW10 Dr Yeh further explained that the brainstem could expand fairly rapidly following tumour removal due to not only decompression (as mentioned above at [186]) but also engorgement by haematoma within the brainstem and MCP itself.[273] I note, however, that PW5 Dr Tang, the Plaintiff's expert neurosurgeon, expressed a different view, which I mention for completeness but do not find to have changed my analysis (because the *Bolam-Bolitho* test does not require the court to prefer one school of thought over another). He said that the pons would only exhibit a "slight shift" back to its original position, unless the surgeon had injured a major artery and caused massive infarct. In the latter situation, there would be immediate swelling and this could possibly lead to rapid rebound of the pons.[274]

202 The First Defendant cited two examples of brainstem rebound within 18 hours after surgery. This was observed in a patient from Khoo Teck Puat Hospital and a patient from Ng Teng Fong General Hospital.[275] The Plaintiff had, in closing submissions, wrongly argued that these examples were irrelevant. The Plaintiff's counsel contended that the scans were taken after a much longer timeframe than 18 hours – more precisely, five days apart for one patient and two months apart for another[276] – but this view was incorrect. The Plaintiff corrected this after the Defendants pointed this out.[277] The First

---

272 17/7/19 NE 174.

273 17/7/19 NE 173.

274 8/5/19 NE 126-127; 10/5/19 NE 183.

275 1D12.

276 PCS at para 154.

277 PRS at para 75.

Version No 1: 27 Oct 2020 (22:41 hrs)

Defendant opined that the Plaintiff's pons would have rebounded faster because of venous swelling in the brainstem.[278] I accept that these examples support the view that a compressed pons can rebound.

203 PW5 Dr Tang had cited a case study relating to a three-year-old girl to support his view that the pons generally would not rebound. But in PW5 Dr Tang's case study there is a large age difference with that of the Plaintiff. Furthermore, the tumours involved were different. In PW5 Dr Tang's case she had an ependymoma, *ie*, a tumour arising from the ependyma, a tissue of the central nervous system – in paediatric cases it is located at the fourth ventricle. However, in this case the Plaintiff had a large vestibular schwannoma located at the cerebellopontine angle which is at the margin of the cerebellum and the pons.[279]

204 Fourthly, the Plaintiff asserts that the extra-axial haematoma in the tumour cavity meant that the tumour cavity would have been occupied by blood and haematoma which exerted pressure (in lieu of the tumour) that was sufficiently great to prevent the Plaintiff's pons from rebounding. But there is no evidence to compare the pressure caused by the hardness or density of the solid and cystic parts of the tumour with that of a haematoma at various stages of coagulation. Whether the extra-axial haematoma could prevent the pons from rebounding will largely depend on the interplay between the elasticity of the brainstem, the force exerted by the extra-axial haematoma, the progression of the extra-axial haematoma and that of any intra-axial pontine haematoma that might be found to exist.

---

278 14/5/19 NE 97.

279 D1CS at para 197.

Version No 1: 27 Oct 2020 (22:41 hrs)

205 From the evidence, it is more probable and logical that the pons could have and had indeed rebounded, as observed by DW11 Dr Pang, between the time of the First Surgery to the time of the First CT Scan. DW11 Dr Pang's observation of the pons rebounding is first-hand and direct evidence. I have no reason to doubt his testimony.

206 The First Defendant was not asked whether he had seen the pons rebounded but he had stated clearly that the pons had rebounded into the tumour cavity. It is safe to infer that he had seen the pons rebounded, just like DW11 Dr Pang, as he was the lead surgeon in removing the tumour of the Plaintiff.

207 The fact that the Plaintiff's pons had rebounded is a very significant, if not decisive, factor in determining whether the haematoma in the tumour cavity was extra-axial or intra-axial or both. Given my finding that the Plaintiff's pons had rebounded, I would prefer the interpretation of the witnesses who had made that assumption in interpreting the First CT Scan, these being DW4 Dr Ivan Ng, DW10 Dr Yeh, DW16 Dr Yu, DW3 Dr Hong, DW11 Dr Pang and the First Defendant. PW3 Dr Gan and PW5 Dr Tang, the Plaintiff's neurosurgeons, had also said the pons had rebounded slightly although they opined that the haematoma in the tumour cavity was extra-axial.

(2) Plaintiff's clinical presentation just before the Second Surgery

208 The following issues are relevant at this stage:

(a) whether the First Defendant and/or his team noticed that the Plaintiff had pinpoint pupils; and

Version No 1: 27 Oct 2020 (22:41 hrs)

(b) whether the First Defendant's diagnosis of a significant intra-axial pontine haemorrhage was consistent with the Plaintiff's clinical presentation.

209 The First Defendant explained that the Plaintiff had bilateral pinpoint pupils when she was examined by DW12 Dr Low before the Second Surgery. The pinpoint pupils revealed that the Plaintiff had an intra-axial pontine brainstem lesion. He said that it was not the extra-axial haematoma that was compressing the pons from the outside.

210 I am satisfied that DW12 Dr Low *had* seen the Plaintiff's bilateral pinpoint pupils. He noticed that the Plaintiff was in a coma and was in poor GCS state so he retracted her eyelids and shone a light on her pupils. He found them to be pinpoint. The First Defendant was informed that the Plaintiff had pinpoint pupils before the decision on treatment was taken after reading the First CT Scan.

211 Although the First Defendant insisted that bilateral pinpoint pupils indicated *only* intra-axial haemorrhage and not extra-axial haematoma compressing the brainstem externally,[280] I do not find the evidence to go that far. DW3 Dr Hong, PW3 Dr Gan and PW5 Dr Tang testified that pinpoint pupils would result from anything affecting the pons.[281] Against this, DW12 Dr Low testified that pinpoint pupils would suggest an *intrinsic* pontine injury such as pontine haemorrhage, stroke or infarction, and not extrinsic compression.[282] Accordingly, even if the First Defendant had observed pinpoint pupils before

---

280 15/5/19 NE 57.

281 10/7/19 NE 68; 8/5/19 NE 75; 25/4/19 NE 95-96.

282 18/7/19 NE 196.

Version No 1: 27 Oct 2020 (22:41 hrs)

making his diagnosis, this is not decisive but at most *one* relevant factor that impacted his assessment of whether the haematoma in the tumour cavity was intra-axial or whether the haematoma was extra-axial and compressing the pons from the outside.

212 Next, the Plaintiff's experts, namely PW5 Dr Tang and PW3 Dr Gan, opined that if the haematoma were intra-axial, the Plaintiff must have been paralysed on both sides and comatose, but that was not the case here.[283] Reliance was placed on a table by Louis Caplan ("Caplan's table"),[284] to show that if there was a central pontine bleed the patient would be in coma and quadriplegic (*ie*, paralysis of both sets of limbs). Caplan's table states:[285]

Signs	**Consciousness**	**Motor**	**Sensory**	**Pupils**	**Oculomotor**
Central pontine	Coma	Quadriplegia	Normal	Small reactive	Bilateral horizontal gaze palsy
Unilateral basal	Normal	Contralateral hemiplegia-ataxia	Contralateral paresthesia	Normal	Normal
Unilateral basal-tegmental	Normal	Contralateral hemiplegia-ataxia	Contralat[e]ral paresthesia	Normal	Ipsilateral horizontal gaze palsy or sixth nerve palsy
Lateral tegmental	Normal	Ipsilateral ataxia	Contralateral hemisensory loss	Ipsilateral Horner	Ipsilateral horizontal gaze palsy; one-and-a-half syndrome

213 DW3 Dr Hong explained that the Plaintiff's clinical presentation was consistent with Caplan's table. It does not necessarily follow that a central pontine haemorrhage means that the patient would be in a coma or quadriplegia.

283 7/5/19 NE 54-65.

284 PBD5 at slide 13.

285 PBD5 at slide 13.

Version No 1: 27 Oct 2020 (22:41 hrs)

Much would depend on the size of the haemorrhage. Small brainstem haemorrhage including central pontine haemorrhage would not always result in coma or quadriplegia.[286] A big haemorrhage in the middle of the pons would cause quadriplegia or coma. Haematomas would take a while to manifest and as they evolved the patient's clinical presentation would change.[287] DW3 Dr Hong also emphasised that the *timing* of assessment was important, given that this was a rapidly changing situation.[288] At 1820 hrs the Plaintiff's GCS was 10 and this had dropped to 3–4, which means she was in deep coma (GCS 3), by 1850 hrs.

214 The Plaintiff's clinical presentation preceding the Second Surgery was, therefore, very poor. She ended up in deep coma with GCS of 3 by 1850 hrs, and had bilateral pinpoint pupils which was consistent with pontine haemorrhage.

(3) Radiological features on the First CT Scan

215 The First Defendant relies on the following to support his view that there was significant intra-axial pontine haematoma:

(a) The haematoma in the tumour cavity is greyer in colour compared to the surgical tract haematoma. A haematoma will appear greyer if it is intra-axial compared to a whiter extra-axial haematoma, because the former is mixed with brain tissue and less dense.[289]

---

286 9/7/19 NE 103–104.

287 9/7/19 NE 116–117.

288 10/7/19 NE 52–54.

289 14/5/19 NE 64-65.

Version No 1: 27 Oct 2020 (22:41 hrs)

(b) The haematoma in the tumour cavity was separated from the surgical tract haematoma by a thin grey line, which he identified as corresponding to the surface of the pons. There is also a grey finger or tongue visible between the two haematomas on the coronal images.[290] The tongue or tissue is cerebellar tissue, which would be absent if the haematoma were entirely extra-axial. Whatever is medial (*ie*, towards the centre) of the tongue would be within the brainstem.[291]

Clean image	**Annotated image**
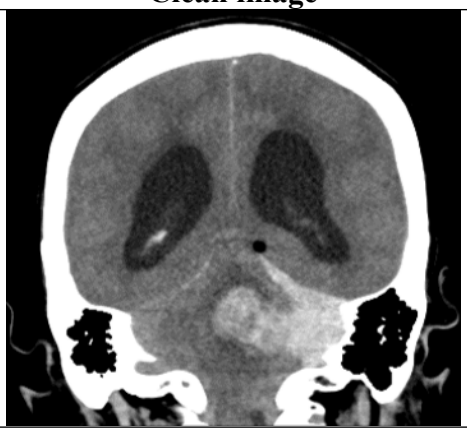	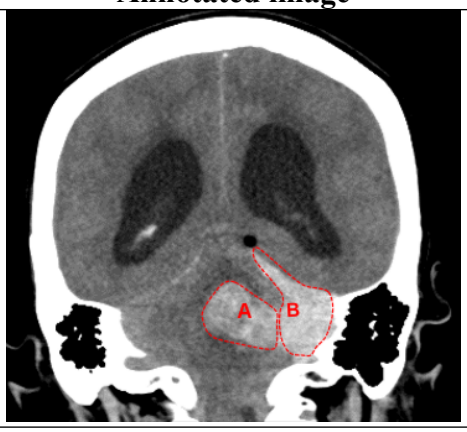
Coronal view from the First CT Scan. Thin grey line referred to is the narrow strip between A and B. Finger/tongue or tissue is the larger strip between A and B.	

(c) The air bubbles, represented by dark circles in the surgical tract, did not violate the thin grey line but instead remained in extra-axial space.

(d) There was very significant oedema and swelling in the brainstem and cerebellum. A purely extra-axial haematoma would not have caused such large amounts of oedema and swelling.

---

290 DBRI 16.

291 14/5/19 NE 73-75.

Version No 1: 27 Oct 2020 (22:41 hrs)

(e) The lack of a clear plane between the haematoma and the brainstem (*ie*, the presence of a "fuzzy border") indicated the presence of haematoma within the brainstem.[292]

216 Regarding the factor at [215(a)] above, the Plaintiff contends that the colour difference is attributed to the age of the haematoma and the stage of coagulation (as PW4 Dr Pay had testified) rather than whether the haematoma is intra-axial or extra-axial. The brighter areas represent older haematoma whereas the darker shades of grey represent fresher blood. I accept PW4 Dr Pay's explanation. The First Defendant was wrong in stating that the brighter areas represented *newer* haemorrhage, as seen from the subsequent evidence of his own experts. Therefore, this factor does not support the First Defendant's diagnosis. I shall turn to examine the other reasons of the First Defendant.

217 Regarding the factors at [215(b)] above, DW10 Dr Yeh agreed that the tongue of grey represented brain tissue (specifically, cerebellum and a bit of the pons).[293] PW5 Dr Tang also thought it was cerebellar tissue.[294] The Plaintiff's counsel challenged the First Defendant's identification of the thin grey line as the outer surface of the pons. He relied on PW4 Dr Pay's postulation that the thin grey strip could either be: (i) a part of the tumour septum that was left behind (the tumour septum apparently referring to strips of tissue within the cystic part of the tumour); or (ii) unclotted blood within a haematoma which

---

292 D1CS at paras 230-234.

293 19/7/19 NE 51.

294 8/5/19 NE 157.

Version No 1: 27 Oct 2020 (22:41 hrs)

was at different stages of coagulation.[295] I shall now analyse PW4 Dr Pay's explanation.

(a) I reject explanation (i). PW4 Dr Pay acknowledged that he had no personal knowledge of any septum or capsule that was left behind.[296] DW12 Dr Low, who was one of the surgeons assisting the First Defendant at the First Surgery, testified that there was no septation (division between cavities or parts of the tumour by partitions or septa) left behind. However, he said that a bit of the tumour capsule that was stuck to the brainstem was left behind.[297] DW10 Dr Yeh pointed out that even if the thin grey line were tumour capsule, that would lie on the *surface* of the brainstem and it implied that the haematoma was in two different compartments. Thus, he agreed with the First Defendant that part of the haematoma was in the pons.

(b) I also reject explanation (ii). DW16 Dr Yu explained that an area of "isodensity" simply means an area that *appears* to be of the same density as brain tissue *ie*, "iso" meaning the same and normal brain tissue being the comparator. Thus, the appearance of isodensity could be interpreted as either unclotted blood, hyperacute haematoma or brain tissue, and isodensity *per se* is not conclusive of which interpretation to prefer.[298] It would also be necessary to have regard to other factors such as the shape and border of the haematoma. DW10 Dr Yeh thought it

---

295 2/5/19 NE 147–151; 3/5/19 NE 87.

296 3/5/19 NE 97.

297 18/7/19 NE 172.

298 13/8/19 NE 11-12.

Version No 1: 27 Oct 2020 (22:41 hrs)

would be unusual for haematoma to take such a "very thin and very linear" shape.[299]

218 Regarding [215(c)] above, the Plaintiff's counsel contends that the air bubbles did indeed violate the thin grey line, referring to the image on the left below where the black air bubble appeared to encroach into the strip of grey.[300] In similar vein, the Plaintiff's counsel argues that the air bubble appeared to encroach on the pons as drawn by the First Defendant (blue outline in the image on the right), alternatively that the pons appeared to wrap around the air bubble, which defied physics.[301]

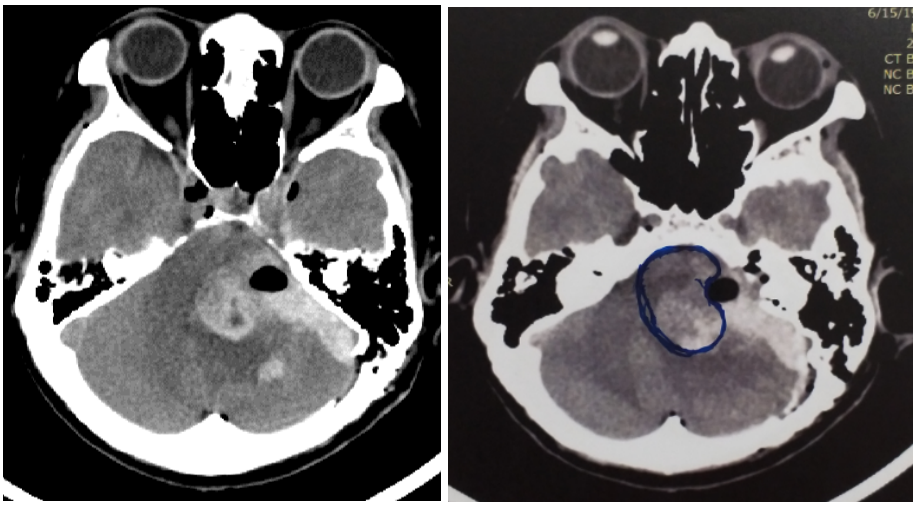

Axial view from the First CT Scan.

299 17/7/19 NE 95-96.

300 PCS at para 166.

301 PCS at para 168.

Version No 1: 27 Oct 2020 (22:41 hrs)

The First Defendant explained that the encroachment of the air bubble into the strip of grey was an artifact (*ie*, an anomaly in the CT scan image). [302] This explanation is supported by DW10 Dr Yeh's evidence. DW10 Dr Yeh explained that the slight indentation was explicable by limitations in the CT scan technology (which tended to over-exaggerate the boundaries of an air bubble due to the large density difference at the junction).[303] The First Defendant also clarified that it was the blood in the extra-axial space and not the air bubble that shaped the pons. He further added that it was by chance that an air bubble floated into the blood occupying that region in this particular CT scan image.[304] This was supported by the evidence of DW4 Dr Ivan Ng, who explained (albeit by reference to a cut three slices down) that the air bubble was likely to be where the junction of the brainstem and the blood was.[305] It is difficult to reject the First Defendant's explanation, which is supported by his experts.

219 Regarding [215(d)] above, PW5 Dr Tang accepted that by the time of the First CT Scan there was significant oedema and swelling in the brainstem and cerebellum.[306] PW2 Dr Chua also drew a fairly large region of oedema (the c-shaped portion in the image below) that encompassed the region he marked as pons.

---

302 16/5/19 NE 152.

303 17/7/19 NE 164-165.

304 16/5/19 NE 145.

305 11/7/19 NE 51.

306 9/5/9 NE 24.

Version No 1: 27 Oct 2020 (22:41 hrs)



Axial view from the First CT Scan.

220 The Plaintiff's counsel's argument is that the significant oedema could have been *pre-existing* before 1 June 2014. However, this is contradicted by DW16 Dr Yu, who opined that having regard to the slow growth rate of acoustic neuromas, additional vasogenic oedema due to compression by the tumour was less likely to occur in the intervening month between the First CT Scan and the RadLink MRI.[307]

221 The Plaintiff's alternative contention is that the existence of significant oedema was attributable to (and consistent with) the presence of solely extra-axial haematoma in the surgical tract and tumour cavity. The Plaintiff relied on the evidence of PW2 Dr Chua, who, when asked why there would be such a significant degree of oedema when the blood was occupying the space just created in the brain after the removal of the tumour, explained that the pressure would *also* result from the surgical tract haematoma, which did not exist before

307 5/8/19 NE 124.

Version No 1: 27 Oct 2020 (22:41 hrs)

the First Surgery.[308] However, DW16 Dr Yu opined that the left posterior fossa haematoma (the surgical tract haematoma, plus the haematoma in the tumour cavity) was similar in total size to the tumour on the RadLink MRI.[309] DW16 Dr Yu pointed out that PW4 Dr Pay himself had already included the surgical tract haematoma in his comparative marking, albeit in a different context:

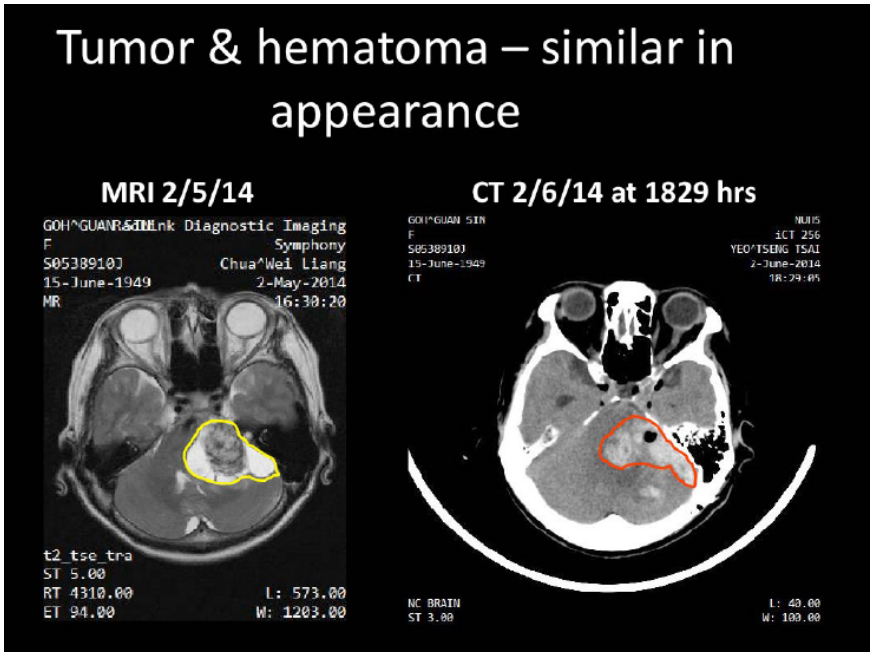

I find DW16 Dr Yu's explanation, that the significant increase in oedema could not be caused by extrinsic compression, to be a logical one.

222 Regarding [215(e)] above, that a fuzzy border would indicate intra-axial haematoma was the evidence of DW4 Dr Ivan Ng, DW16 Dr Yu, and DW10

308 30/4/19 NE 75.

309 2D6 at slide 71.

Version No 1: 27 Oct 2020 (22:41 hrs)

Dr Yeh.[310] The reason for the fuzzy border was that there was irregular extension of blood into the brain tissue. Conversely, a sharp border would be observed for an extra-axial haematoma because of how the haematoma had to rest on the surface of the brainstem.[311] The Plaintiff's counsel challenged this by arguing that a similar "fuzzy border" could be seen even at the site of the surgical tract, which was clearly extra-axial. The upshot was that this factor could not be relied on to show an intra-axial haematoma.[312] But the precise point was put to DW16 Dr Yu, who disagreed with the Plaintiff's counsel that the border was unclear.[313] In other words, to the Plaintiff's counsel the border near the extra-axial haematoma was unclear but to DW16 Dr Yu it was. I prefer DW16 Dr Yu's explanation, not simply on the basis of her more extensive experience and training but also for two additional reasons. Firstly, she justified her view by reference to images before and after that image relied on by the Plaintiff's counsel to show why there was a clear plane. Secondly, she even sought to explain why the Plaintiff's counsel could have formed the view he did and why this was ultimately mistaken:[314]

---

310 11/7/19 NE 100-101; 5/8/19 NE 32.

311 19/7/19 NE 291-292.

312 PCS at para 171.

313 6/8/19 NE 57.

314 6/8/19 NE 55–56.

Version No 1: 27 Oct 2020 (22:41 hrs)

> The other reason why, for counsel, he might say this is a little bit fuzzy, is because right next to here is some subarachnoid haemorrhage, and we can see clearly the differentiation between the subdural hematoma with a clear plane and the subarachnoid haemorrhage, which does make it look a little bit fuzzy.

I find DW16 Dr Yu's explanations to be persuasive. I note also that in PW2 Dr Chua's expert report, he had conceded in relation to the First CT Scan that "[t]he plane between the haematoma and the pons is not distinct, hence, it is difficult to determine if the haematoma had extended into the left periphery of the pons".[315] He further added that "one cannot exclude the possibility of small areas of intra-axial haemorrhage at the left periphery of the brainstem since the CT scan has limitation[s]".[316]

223 Finally, I shall deal briefly with PW4 Dr Pay's reliance on his observation that the configuration of the haematoma conformed closely to that of the tumour cavity. The First Defendant sought to rebut this point by adducing a series of images that showed that the medial-most (*ie*, central-most) extent of the haematoma extended beyond the medial-most extent of the tumour cavity when comparing equivalent cuts of the First CT Scan and the RadLink MRI.[317] Having regard to the images, I accept the First Defendant's explanation.

(4) My findings on the interpretation of the First CT Scan

224 Considering all three factors identified at [173(b)] above, on the balance of probabilities, I find that the diagnosis of an intra-axial haematoma satisfies the *Bolam-Bolitho* test. The Defendants' experts supported the view that the

---

315 PW2 Dr Chua's AEIC at p 15.

316 PW2 Dr Chua's AEIC at p 23.

317 1D9 at pp 6, 8.

Version No 1: 27 Oct 2020 (22:41 hrs)

Plaintiff's pons rebounded into the tumour cavity, which was a necessary and fundamental condition that justified a diagnosis of intra-axial haematoma. Further, the existence of an intra-axial haematoma was consistent with the Plaintiff's clinical presentation around 1829 hrs and the radiological features on the First CT Scan.

225 I do not accept the other arguments raised by the Plaintiff on this issue.

226 Firstly, the Plaintiff argues that it is incumbent on the First Defendant to be "absolutely certain" that the diagnosis ruling out the Plaintiff's chances of survival (*ie*, a diagnosis of substantially intra-axial haematoma) is correct, and that the question must be framed in terms of whether the diagnosis of an extra-axial haematoma can be safely ruled out.[318] But a standard of absolute certainty would impose an impossibly demanding standard on doctors, especially given the tremendous difficulties faced by the Plaintiff's and Defendants' experts in interpreting the First CT Scan.

227 Secondly, the Plaintiff contends that the First Defendant's diagnosis of a brainstem haematoma was not accepted by any of his own experts.[319] It is alleged that while some of his experts agreed that there may have been *some* intra-axial haemorrhage, none of them were prepared to endorse his interpretation of the First CT Scan as involving a *very substantial and central* brain stem haemorrhage. The First Defendant, while acknowledging that each witness has his or her individual interpretation of the shape and extent of the haematoma, argues that there can be a plurality of views on diagnosis which

318 PRS at para 48.

319 PCS at paras 132b, 148.

Version No 1: 27 Oct 2020 (22:41 hrs)

accord with the standard of care as long as these are supported by logic and reason. The general consensus amongst the Defendants' experts is that there was intra-axial pontine haemorrhage. The difference is only to the degree. I have already rejected this contention above (at [195]) in relation to variations regarding the extent of pontine rebound and those views apply equally here.

228 Thirdly, the Plaintiff argues that the issue on whether the pons did rebound into the tumour cavity was not discussed in the affidavits of the Defendants' experts. The explanation is very simple. The approach of the Plaintiff's and Defendants' experts in the interpretation of the CT scan was to rely on the various landmarks in the posterior cranial fossa for their conclusions. Having read their expert reports and their testimonies it was obvious that their interpretation of whether it was extra-axial or intra-axial haematoma was based heavily on their assumption of the location of the pons after the First Surgery. To each of the experts his or her assumption about the location of the pons did not seem controversial until at the trial when the experts' interpretations of the First CT Scan were subjected to very intense scrutiny during the cross-examination. It was then discovered that the Plaintiff's and Defendants' experts had different assumptions on whether the pons rebounded after the First Surgery. Moreover, as the First Defendant pointed out,[320] DW10 Dr Yeh had in fact stated in his report that "[t]he tumour had already been excised at point of scan … and as such, any 'severe deformity and displacement' of the pons and medulla *would have been corrected to large extent*" [emphasis added].[321] Even though he did not say so in express terms, the reference to the position of the

320 D1RS at para 49.

321 DW10 Dr Yeh's AEIC at p 22, para 18b.

Version No 1: 27 Oct 2020 (22:41 hrs)

pons is clear. Accordingly, I do not give much weight to the Plaintiff's argument on this issue.

229 For completeness, I also reject the Plaintiff's two other contentions that the First Defendant was negligent by failing to consult a radiologist in interpreting the scan,[322] or by not placing the RadLink MRI scan side-by-side in the scan room.[323]

230 Regarding the failure of the First Defendant to consult a radiologist, DW4 Dr Ivan Ng stated that neurosurgeons read their own scans and it would be unnecessary to consult a radiologist, particularly in acute scenarios.[324] For that reason, it would not matter even if there was a way to contact a radiologist (by handphone, or even when the radiologist was at home because the radiologist had the requisite software to look at the scans), as the Plaintiff argued.[325] Similarly, DW3 Dr Hong and PW5 Dr Tang testified that in an emergency situation they would not rely on a radiologist to interpret scans.[326] DW16 Dr Yu's view was that in an emergency situation with acutely deteriorating patients, it was up to the surgeon whether to contact a radiologist, bearing in mind that this would result in further delays in management.[327]

231 Regarding the failure to place the RadLink MRI scan side-by-side with the First CT Scan, the First Defendant testified that he had read the MRI scans

---

322 PCS at para 184.

323 PCS at paras 144, 183.

324 11/7/19 NE45.

325 PCS at para 184.

326 8/7/19 NE 47; 8/5/19 NE 123-124.

327 5/8/19 NE 75.

Version No 1: 27 Oct 2020 (22:41 hrs)

beforehand and that he had a good recollection of them as the RadLink MRI scan was used to assist him during the First Surgery that morning.[328] Thus, he would have the confidence to interpret the CT scan at 1829 hrs without the RadLink MRI scan that he used less than a few hours ago. I do not accept the Plaintiff's contention that the First Defendant's testimony of having a good memory of the MRI scans was self-serving and should not be believed.[329] The Plaintiff's basis for saying this is that there were 13 MRI films each with many images and so it would be impossible to remember them all or even the more important scans with "intricate and specific details". No expert testified that it was necessary to recall every single detail of each scan in order to arrive at a conclusion whether the haematoma was intra-axial or extra-axial.

Decision to insert an EVD as the sole surgical response

232 This is not a "pure diagnosis" case (see [108] above), thus, the First Defendant's interpretation of the First CT Scan must be seen in conjunction with the course of treatment he prescribed for the Plaintiff. The issue here is whether the First Defendant fell below the requisite standard of care in deciding to insert an EVD as the sole surgical response to his diagnosis of significant pontine haematoma. Around the time of the First CT Scan, the Plaintiff had Cushing reflex as her intracranial pressure in the posterior cranial fossa was building up. This was due to the accumulation of the haemorrhage, haematoma and hydrocephalus.

233 It was undisputed that the Plaintiff would have died if nothing had been done. The experts on both sides accepted that the insertion of an EVD was

---

328 22/5/19 NE 47.

329 PRS at para 43.

Version No 1: 27 Oct 2020 (22:41 hrs)

necessary[330] and that the insertion of an EVD saved her life.[331] The Plaintiff's experts also accepted that any intra-axial component of the haematoma should *not* be evacuated because doing so would be dangerous and cause unacceptable damage.[332] The disagreement is over what else should have been done – in particular, whether the extra-axial component of the haematoma should have been evacuated in addition to inserting the EVD.

234 The Plaintiff's primary position is that surgical evacuation was the appropriate treatment of a mostly extra-axial haematoma.[333] The Plaintiff's alternative submission is that even if there had been a limited intra-axial component, the evacuation of the extra-axial aspect of the haematoma would have returned the Plaintiff to a state of some functional recovery (albeit with deficits).[334]

235 The First Defendant contends that it was reasonable to only insert an EVD. It would have been futile to evacuate the extra-axial haematoma in the surgical tract due to the intra-axial pontine haematoma which resulted in a very poor prognosis. In fact, evacuating the haematoma would have entailed a risk of making things worse by damaging more cranial nerves, brainstem, and cerebellum.[335] That said, he would have evacuated the haematoma if it were completely extra-axial *and* the patient were in a reasonably good neurological state (rather than GCS 3–4 as she was at 1850 hrs).

---

330 25/4/19 NE 55; 7/5/19 NE 101.

331 9/5/19 NE 57-58.

332 25/4/19 NE 82; 8/5/19 NE 35.

333 PCS at para 240.

334 PCS at para 240.

335 Dr Yeo's AEIC at paras 107, 119, 122; 14/5/19 NE 151-152.

Version No 1: 27 Oct 2020 (22:41 hrs)

236 Although the opinions of the Plaintiff's and Defendants' experts were diametrically opposed on whether the haematoma should be evacuated, both sides proceeded on the basis that this decision should be arrived at by applying a risk-benefit calculus. I shall therefore proceed by analysing two scenarios:

(a) On the basis that there was pontine haematoma (as found at [224] above): Should the extra-axial haematoma have been evacuated ("Case A")?

(b) Would the analysis change if the haematoma were entirely extra-axial (as the Plaintiff contends) ("Case B")?

Case A: Intra-axial pontine haematoma

(1) The Plaintiff's prognosis

237 The Plaintiff's counsel argues that pontine haemorrhage does not necessarily confer a poor prognosis. The evacuation of the extra-axial aspect of the haematoma would have returned her to a degree of functional recovery albeit with deficits.[336] He relied on:

(a) A textbook by Louis Caplan ("the Caplan textbook") which stated that patients with small pontine haematomas generally survive with slight to moderate clinical neurological deficits.[337]

(b) An article by Dr Rou-chen Jee ("the Jee article"),[338] which reported a patient who had a large left cerebellopontine angle tumour

336 PCS at para 240.

337 PRS at para 115.

338 PW5 Dr Tang's AEIC at p 446.

Version No 1: 27 Oct 2020 (22:41 hrs)

which compressed the pons and cerebellar peduncle. After surgery to remove the tumour, she developed a left pontine haemorrhage. She underwent an aggressive rehabilitation programme and ended up with a "good functional outcome" after one year.

(c) An article by Karen Chua and Keng-He Kong ("the Chua and Kong article"), which stated that "despite the occurrence of multiple physical deficits after vascular insult to the brain stem, this group of brain stem stroke patients clearly makes significant functional gains in mobility and self-care skills …".[339]

(d) An article by Charles Tator and Farhad Pirouzmand ("the Tator article"). This states that "In the presence of severe worsening neurologic deficit, surgical removal [of pontine haematomas] should be undertaken even though the contralateral limb weakness and ipsilateral limb ataxia will usually persist to a significant extent".[340]

(e) An article by Reza Behrouz ("the Behrouz article") to show that: (a) the overall all-cause mortality for pontine haemorrhage was roughly 50%; and (b) 74 out of 171 patients with pontine haemorrhages experienced good to moderate recovery of functional outcome, albeit with some neurological deficits.[341]

---

339 PW5 Dr Tang's AEIC at p 445.

340 PW5 Dr Tang's AEIC at p 362.

341 PRS at paras 112-114.

Version No 1: 27 Oct 2020 (22:41 hrs)

(f) A table reproduced in the Behrouz article ("Huang's table") to argue that the chances of mortality in the Plaintiff's case was not high. Huang's table tabulates the chance of mortality depending on the patient's GCS score and haemorrhage volume, and states:[342]

Feature	**Point**
GCS Score	
3–4	2
5–7	1
8–15	0
Haemorrhage volume	
> 10ml	2
5–10ml	1
< 5ml	0
Score	mortality
0	2.7%
1	31.6%
2	42.7%
3	81.8%
4	100%

238 The Defendants' experts and the Plaintiff's expert, PW3 Dr Gan, took a contrary view. DW3 Dr Hong explained that because the brainstem has many

342 PW5 Dr Tang's AEIC at p 461.

Version No 1: 27 Oct 2020 (22:41 hrs)

important structures in a very small space, a small haematoma in that space can still do a lot of harm.[343] It sufficed to be "very, very bad" that there was a small area of haematoma in the brainstem, which would itself result in severe neurological damage and disability.[344] Whatever was done, the result would be poor and even removing the extra-axial component of the haematoma would not result in substantial improvement.[345] PW3 Dr Gan agreed[346] and opined that if the haematoma was in the brainstem, evacuation was possible but most people would not do so *because the outcome would be poor* given the size of the haematoma.[347] It was also DW4 Dr Ivan Ng's position that "[b]rainstem haemorrhage connotes a poor prognosis and surgical evacuation would not change the outcome (i.e., allow the patient to experience functional recovery)".[348]

239 I am satisfied that the Defendants' position that an intra-axial haemorrhage carries a poor prognosis satisfies the *Bolam-Bolitho* test, having regard to the evidence from both sides. That is so notwithstanding the textbooks and articles relied on by the Plaintiff, which I shall deal with in turn.

(A) THE CAPLAN TEXTBOOK, THE JEE ARTICLE, THE CHUA AND KONG ARTICLE AND THE TATOR ARTICLE

240 The First Defendant contends that the Caplan textbook, the Jee article, the Chua and Kong article, and the Tator article were all irrelevant to brainstem

---

343 10/7/19 NE 31.

344 2D5 at slide 21.

345 8/7/19 NE 75, 228.

346 26/4/19 NE 104-105.

347 26/4/19 NE 177.

348 DW4 Dr Ivan Ng's AEIC at p 59.

Version No 1: 27 Oct 2020 (22:41 hrs)

haematomas. The former three related to brainstem stroke[349] while the Tator article stood only for the limited proposition that intra-cerebellar haematomas should be evacuated.[350]

241 The First Defendant's contention is supported by DW3 Dr Hong, who explained that stroke or spontaneous cerebellar haemorrhage involves different risks and management to brainstem haemorrhage.[351] The structures encountered when removing the haematoma in the case of cerebellar haemorrhages would only be cerebellar tissue which has a propensity to recover (especially when only virgin, hitherto uninjured brain tissue was involved), and there was no risk of meeting any cranial nerves. Further, cerebellar clot could be removed more easily because there was a clear demarcation between the clot and cerebellum; as haematoma was removed more clot would be squeezed out by the pressure of the underlying cerebellum. In contrast, the tumour had already damaged part of the Plaintiff's brain and subsequent surgical manipulation aggravated the damage. There were also cranial nerves running through the middle of the haematoma in the Plaintiff's case and the consistency of the haematoma near the brainstem would be like that of salted egg yolk such that hard sucking and rinsing would be necessary to remove it.[352] Thus, the risk of damage to the brainstem would be higher. DW3 Dr Hong's explanation is logical and defensible, and I accept it on the *Bolam-Bolitho* standard.

---

349 D1RS at Annex A, p 3.

350 D1RS at Annex A, p 3.

351 10/7/19 NE 25-28.

352 9/7/19 NE 140.

Version No 1: 27 Oct 2020 (22:41 hrs)

242 I wish to make two points regarding the Chua and Kong article and the Caplan's table respectively. These would further diminish the relevance of these articles to this case.

(a) The Chua and Kong article concerned a biased sample. PW5 Dr Tang was asked in cross-examination whether he should have pointed out to the court that the article concerned a pre-selected group of patients who were suitable for rehabilitation. PW5 Dr Tang accepted that it was a biased group but added that the article was "for everybody to read".[353]

(b) The Plaintiff argued that applying Caplan's table, the existence of an intra-axial haematoma to the extent identified by DW10 Dr Yeh and DW16 Dr Yu would be classified as a unilateral basal or lateral tegmental haemorrhage (see the figure below).[354] These one-sided haemorrhages were reversible and did not indicate a poor prognosis *per se*, such that the First Defendant should not have written the Plaintiff off but proceeded to evacuate the extra-axial component of the haematoma. In this regard, PW5 Dr Tang opined that only one type of pontine bleed carried a poor prognosis – a central pontine bleed. Any other pontine haemorrhage, be it large or small that involves only half the pons, would not.[355]

---

353 8/5/19 NE 49-50.

354 PCS at para 232.

355 8/5/19 NE 52.

Version No 1: 27 Oct 2020 (22:41 hrs)

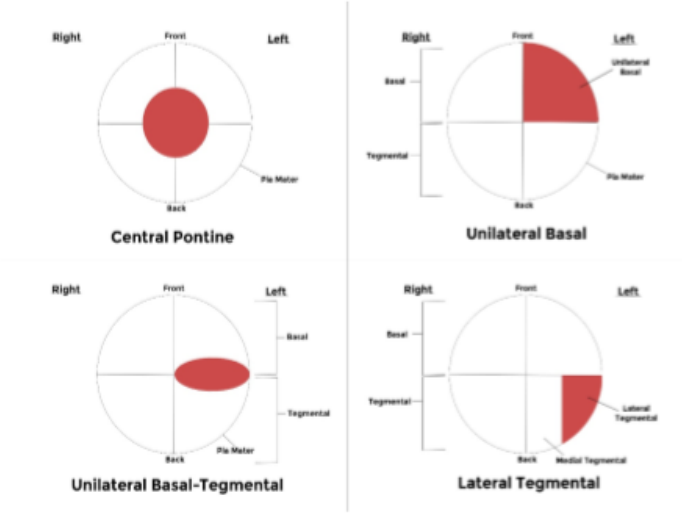

However, when brought to Caplan's table, DW16 Dr Yu stated that her opinion was that the haematoma was in the *central* pons.[356] This was her conclusion, notwithstanding her earlier acknowledgement that the haematoma *could also* be in the lateral left side of the pons because it was difficult to determine where exactly the pons was.[357] Given the Plaintiff's misconstruing of DW16 Dr Yu's evidence, this particular point regarding Caplan's table does not assist the Plaintiff. DW10 Dr Yeh was not asked to comment on this aspect of his evidence. However, the area he identified as pons was larger than, and appears to encompass, the area identified by DW16 Dr Yu as pons. Given that DW16 Dr Yu's evidence is that what she identified is central pons, that observation applies *a fortiori* to DW10 Dr Yeh.

356 6/8/19 NE 71.

357 6/8/19 NE 68.

Version No 1: 27 Oct 2020 (22:41 hrs)

(B) THE BEHROUZ ARTICLE AND HUANG'S TABLE

243 I shall now turn to Huang's table, which is reproduced in the Behrouz article.

244 The First Defendant points out in closing submissions that Huang's table was published only in 2017, three years after the First Surgery, and pertained to primary pontine haemorrhage (*ie*, stroke caused by hypertension) rather than the Plaintiff's case of post-operative haematoma.[358] Nonetheless, the First Defendant was content for the court to ascribe some value to Huang's table and I shall proceed on that basis.

245 The First Defendant pegged the volume of haemorrhage in the tumour cavity at about 6.5ml and PW5 Dr Tang was content to proceed on that basis.[359] The key differentiating factor would thus be the GCS score. The point of contention is which GCS (taken at what point in time) is relevant.

246 According to the First Defendant, the correct GCS score to use was GCS 3 to 4 at 1850 hrs because that would reflect the reality of the patient's neurological state:[360]

> The GCS score you should apply is obviously ***the score that is closest to the CT scan*** because it reflects reality of the patient's neurological state just around the time of scan, *either just pre or just post.* [emphasis added in italics and bold italics]

He went on to explain why that would be the GCS of 3 to 4:[361]

---

358 DC1S at para 327.

359 Dr Yeo's AEIC at p 18; 10/5/19 NE 163.

360 14/5/19 NE 144-145.

361 14/5/19 NE 149.

Version No 1: 27 Oct 2020 (22:41 hrs)

> Well, her GCS was 3-4 at the end of the CT scan. Because our CT scanner room is very close to the [operating room], you know. In the [operating room] there is note that it was 3-4 so that would score two points …

On this basis, the Plaintiff's mortality would be 81.8% per Huang's table, and the survivors would be very likely to be in a PVS even if the haematoma were evacuated.[362] I find this to be logical.

247 According to PW5 Dr Tang, it would be incorrect to use the GCS reading at 1850 hrs because by then it would have been too late. That GCS score would reflect a "mixed bag of things" – that is, not only pontine haemorrhage but also "reversible causes"[363] such as hydrocephalus and the extra-axial haematoma, that could "blur the proper GCS scoring".[364] He considered that the GCS score at the point "of diagnosis"[365] or "of admission"[366] or "of presentation" (PW5 Dr Tang used these terms interchangeably) should be used instead:[367]

> Q: … What time of GCS score would be relevant for the purposes of interpreting the scans?
>
> A: Your Honour, the GCS score should be at the time of presentation, as I have emphasised. ***It should be between 1655 hours to 1720 hours.***
>
> …
>
> MR VERGIS: 30?
>
> A: 1730. Sorry, I always mix them. Because that is the first presentations [*sic*]. The first documentation was by the

362 14/5/19 NE 145-149.

363 8/5/19 NE 30.

364 8/5/19 NE 25-26.

365 8/5/19 NE 22; PW5 Dr Tang's AEIC at p 100, para 6.14.1.

366 10/5/19 NE 84.

367 10/5/19 NE 160-162.

Version No 1: 27 Oct 2020 (22:41 hrs)

> nurse at 1655 hours and the first documentation by [DW15] Dr Lu, Gabriel Lu, was 1730 hours.
>
> So the GCS then was 13, at the worse in a range of 13 to 15. So it should be -- according to this Huang scoring, it should be point 0 for GCS.
>
> …
>
> COURT: … when you say the point of presentation, what presentation are you talking about?
>
> A: *The point where it is documented to be weak.*
>
> COURT: So the point of presentation in our case will be what time?
>
> A: *1655 hours by the nurse.*
>
> [emphasis added in italics and bold italics]

In support of this view, PW5 Dr Tang relied on an article by Jun Yup Kim and Hee-Joon Bae ("Jun Yup Kim article")[368] which stated that "GCS score refers to the GCS score at initial presentation (or after resuscitation") (PW5 Dr Tang stated that "initial presentation" was the same as "initial diagnosis"[369]). Similarly, the Plaintiff pointed out that the Behrouz article in which Huang's table was reproduced referred to "admission GCS".[370] Notwithstanding that the Jun Yup Kim article described cases of patients admitted to an emergency department with an acute condition, which was not the Plaintiff's situation, PW5 Dr Tang did not find that this would make a difference to which GCS score he would take.[371] Therefore, PW5 Dr Tang was of the view that the decision to evacuate the haematoma should have been 1655 hrs when the Plaintiff's GCS dropped to 13 with right hemiplegia. Applying Huang's table, this would

---

368 First Defendant's Bundle of Medical Literature, Tab 9, p 29.

369 10/5/19 NE 86.

370 PRS at para 111; PW5 Dr Tang's AEIC at para 460.

371 10/5/19 NE 87.

Version No 1: 27 Oct 2020 (22:41 hrs)

translate to a mortality rate of 31.6% (in other words, an approximately 70% chance of survival).

248 This is illogical. The Second Surgery was done at 1915 hrs and the decision to insert the EVD was made around 1850 hrs (taking into account how the First CT Scan was done at 1829 hrs and the need to discuss the best treatment for the Plaintiff). At 1655 hrs the question of surgical intervention would have been moot because (as I have emphasised) DW14 Nurse Lee could not even have ordered a CT scan of her own accord, much less make any decision to proceed to surgery. Furthermore, the Plaintiff's condition had improved substantially by 1730 hrs.

249 The Plaintiff's alternative argument was that the GCS score of 10 at 1820 hrs should be used instead, because that would be the time closest to the First CT Scan purportedly applying the First Defendant's own logic.[372] The Plaintiff explained that the First CT Scan was taken at 1829 hrs, *ie*, nine minutes after the 1820 hrs reading (GCS 10), while the 1850 hrs reading (GCS 3 to 4) was taken 21 minutes after the First CT Scan. I do not think that is what the First Defendant meant by the "closest" timing and have already set out his reasoning above.

250 Therefore, I am more convinced of the First Defendant's interpretation of Huang's table and his application of the table to the present case. Based on Huang's table, the risk of death was very high at more than 80%. I have to be cautious when using Huang's table as it did not exist at the time of the Second Surgery but was raised by the Plaintiff's expert. In any case, it corroborates, *ex*

372 PRS at para 110.

Version No 1: 27 Oct 2020 (22:41 hrs)

post facto as a matter of medical literature, the First Defendant's and his experts' evaluation that it was very risky to evacuate the haematoma as there was a high risk of death to the Plaintiff.

251 Having regard to the experts' evidence and the state of the medical literature, I find that the Plaintiff's prognosis was poor because she had a pontine haematoma.

(2) The expert's evidence on the proper course of treatment

252 I reiterate that the Plaintiff's and the Defendants' experts agreed that EVD insertion was necessary. The only question was whether the extra-axial haematoma should, in addition, have been evacuated.

253 PW5 Dr Tang considered that the reasonable option would be to evacuate the haematoma, even if the surgeon was not entirely sure whether the haematoma was intra-axial or extra-axial. He explained that the haematoma in the posterior cranial fossa had to be evacuated so as to relieve the pressure.[373]

254 PW3 Dr Gan contended that inserting an EVD without evacuating the haematoma was not acceptable.[374] He opined that the additional risk of evacuating the haematoma was probably "slightly higher", because the pressure on the nerves was already there. The surgeon could simply follow the surgical tract, which was filled with blood and suck out the haematoma.[375] His preferred option was to insert the EVD and evacuate the extra-axial haematoma in the

---

373 8/5/19 NE 35; 9/5/19 NE 37-38.

374 26/4/19 NE 125, 127-128.

375 25/4/19 NE 55-59; 26/4/19 NE 156.

Version No 1: 27 Oct 2020 (22:41 hrs)

same operation. He also found it acceptable to insert an EVD and then do a CT scan, followed by evacuation if the second scan showed enlargement of the haematoma with upward herniation.[376] PW3 Dr Gan preferred the first approach because there would be no time to allow the haematoma to grow. He stressed that in the Plaintiff's situation there would be "nothing to lose". Compared to the patient being in a PVS and requiring a tracheostomy and permanent ventilation, "death may be a better situation than her condition now".[377]

255 On the other hand, DW3 Dr Hong opined that whether to evacuate the extra-axial haematoma would depend on the surgeon's risk appetite. If the surgeon thought that being in a PVS would be worse than death, he would take the risk to evacuate. But if the surgeon preferred to preserve life at all costs, he would not.[378] DW3 Dr Hong disagreed with PW3 Dr Gan regarding the risks involved in the procedure for haematoma removal. DW3 Dr Hong stated that it was not that easy to simply follow the surgical tract. The haematoma might be quite firm and there may not even be a clear tract because the brain was mushy and swollen.[379] Further, it would not be useful to remove only the extra-axial haematoma in the surgical tract because any haematoma in the tumour cavity would be next to the brainstem and would have exerted pressure on the brainstem and thus injured it.[380]

256 DW4 Dr Ivan Ng opined that it would have been reasonable and acceptable to insert an EVD alone, *or* couple this with surgical evacuation of

---

376 PW3 Dr Gan's AEIC at p 39, para 3.3.

377 26/4/19 NE 176.

378 8/7/19 NE 57.

379 9/7/19 NE 130.

380 9/7/19 NE 137.

Version No 1: 27 Oct 2020 (22:41 hrs)

the extra-axial haematoma. The Plaintiff's prognosis was poor due to the existence of brainstem haemorrhage. Surgical evacuation would entail its own risks such as further damage to the brainstem and even death. Evacuating the extra-axial haematoma would be unlikely to change the Plaintiff's condition.[381] In fact, the risk involved in evacuating the haematoma where the brain was swollen would be substantial, though DW4 Dr Ivan Ng could not comment on whether the risk was greater or less than that involved in removing the tumour.[382] He disagreed that up to 50% of the haematoma could be safely removed without coming close to the brainstem. To the contrary, the risk of meeting the brainstem would be "very significant" due to brain swelling arising from the First Surgery, haematoma and haemorrhage in the posterior cranial fossa.[383] However, DW4 Dr Ivan Ng explained that he would have evacuated the haematoma even knowing the patient might die on the table, as he would then know he had done everything humanly possible to help the patient avoid the outcome of being in a PVS. Thus, he shared the same view as PW3 Dr Gan. DW4 Dr Ivan Ng said that ultimately, the decision whether to evacuate the haematoma (assuming it was not purely extra-axial) had a "philosophical element" and was not a "pure medical decision".[384]

(3) My assessment of the First Defendant's approach to treatment

257 I am satisfied that the First Defendant's approach of only inserting the EVD satisfies the *Bolam-Bolitho* test as it is supported by competent neurosurgery professionals. Furthermore, it passes the test of logical reasoning.

---

381 1D14 at slides 69–72; 11/7/19 NE 140–141.

382 11/7/19 NE 161.

383 10/7/19 NE 233.

384 11/7/19 NE 175.

Version No 1: 27 Oct 2020 (22:41 hrs)

Inserting an EVD without evacuating the haematoma was a reasonable course of action, having regard to the comparative risks and benefits.

258 I reiterate that the Plaintiff's prognosis was poor because she had an intra-axial haemorrhage in the pons. The decision whether to evacuate the haematoma is a judgment call as to what a reasonable surgeon would do. Is the surgeon a risk-taker who prefers death over PVS for the patient? Or does the surgeon believe in life preservation at all costs? Under the Physician Pledge of the Medical Council which is based on the "Hippocratic Oath and the Declaration of Geneva" all doctors have taken a vow, *inter alia*, to "maintain due respect for human life". On 2 June 2014 at about 1829 hrs, the First Defendant was faced with the Hobson's choice, in having to choose between death and PVS for the Plaintiff. In my view, *a doctor cannot play God. His solemn duty is to have "respect for human life"*. If the choice is between: (a) risking the Plaintiff's life with a high chance of death to evacuate the extra-axial haematoma, without any certainty of this surgical manoeuvre improving her prognosis of PVS; and (b) inserting an EVD to alleviate her symptoms of Cushing reflex to save her life, though she would remain in a PVS albeit without having to face the additional high risk of death through the evacuation of the haematoma, then the First Defendant cannot be faulted for having chosen the latter. Miracles, although rare, do happen. There are cases in which patients in deep coma woke up from their long slumber. It was reported in the Straits Times on 25 April 2019 that a "[w]oman in coma wakes up 27 years after protecting son in accident" in the United Arab Emirates ("UAE") when the vehicle collided into a school bus.

259 The Defendants' experts' views are logical, convincing and persuasive. Evacuation of the extra-axial haematoma could not have been so simple as opined by the Plaintiff's experts. The surgeons had to navigate the bloody mess

Version No 1: 27 Oct 2020 (22:41 hrs)

in a very confined space full of sensitive cranial nerves of the posterior cranial fossa, that had already been subjected to the trauma of the First Surgery that lasted for four hours. On the other hand, not evacuating the haematoma and leaving the bone flap and skin intact would mean that the pressure (which had been brought down, by EVD insertion, from the critical level that led to Cushing reflex) could have had a tamponade effect to stem the sources of haemorrhage. It was DW3 Dr Hong's evidence that removing pressure could increase haemorrhage if there was a bleeding point.[385]

260 Moreover, evacuating the extra-axial haematoma would have dealt only with the symptoms, and not addressed the root cause of the haemorrhage. At the time of the Second Surgery, the First Defendant did not know the cause of the haemorrhage. Even today, the Plaintiff's experts cannot agree conclusively whether the haematoma and haemorrhage in the tumour cavity were caused by the remnants of the tumour capsule (as PW3 Dr Gan opined),[386] venous infarct arising from the ligation of the SPV (as the First Defendant and DW3 Dr Hong contended), haemorrhage from blood vessels outside the brainstem (which PW5 Dr Tang also identified as a possible cause),[387] or dissection of an extra-axial haemorrhage into the brainstem (which DW4 Dr Ivan Ng proposed). PW2 Dr Chua, amongst other experts, could not tell the source of the haemorrhage in the tumour cavity from the CT scan.[388] Evacuation of the haematoma would, therefore, not be a prophylactic solution. Failure to identify the source of the haemorrhage would simply be *déjà vu*, with haemorrhage recurring after the

---

385 9/7/19 NE 137-138.

386 PW3 Dr Gan's AEIC at p 39.

387 PW5 Dr Tang's AEIC at p 92.

388 2/5/19 NE 48.

Version No 1: 27 Oct 2020 (22:41 hrs)

Second Surgery. But to search for the source or sources of the haemorrhage would be akin to looking for a needle in a haystack, as the surgical tract and tumour cavity were messy and filled with haematoma, CSF and blood. Indeed, further injury to the brain structures in the posterior fossa would be very difficult to avoid and there was a real possibility of losing the Plaintiff in the process.

261 I have explained why only inserting an EVD would be an acceptable surgical response supported by the *Bolam-Bolitho* test. Next, I shall address the dispute of whether the First Defendant had in fact adopted PW3 Dr Gan's less-preferred (but nonetheless acceptable) approach of inserting an EVD before doing a CT scan to reassess the situation, or whether this was a belated attempt to take advantage of PW3 Dr Gan's evidence. The Plaintiff's counsel argues in favour of the latter interpretation. He latches onto portions of the First Defendant's evidence where he states that it was never his intention to evacuate the extra-axial haematoma because of the significant brainstem haemorrhage and that the Second CT Scan was only to confirm the position of the EVD and assess the hydrocephalus.[389]

262 I am of the view that the First Defendant and his team adopted PW3 Dr Gan's two-step approach, though the First Defendant did not expressly say so in his evidence. I shall explain my finding below. This finding further weakens the Plaintiff's post-operative allegations of negligence bearing in mind that the Plaintiff's cut-off time for the allegation of negligence is 2013 hrs.

263 Amongst the three doctors who discussed the Second Surgery, DW11 Dr Pang's evidence was the most explicit about the two-step approach. From

---

389 Dr Yeo's AEIC at para 54; 16/5/19 NE 17–18.

Version No 1: 27 Oct 2020 (22:41 hrs)

DW11 Dr Pang's evidence, the options for treatment were actively discussed amongst the First Defendant and DW12 Dr Low at the time when they were deciding the best option to save the Plaintiff.[390] He also explained that a second CT scan at 2013 hrs would serve two purposes: ensuring the EVD was correctly placed, and allowing for re-evaluation of changes especially changes pertaining to the haematoma. As things transpired the Second CT Scan put it beyond doubt, in their minds, that there was a brainstem haematoma by 2013 hrs that extended from the pons to the midbrain and thalamus. They decided against any further intervention. This is the evidence of DW11 Dr Pang: [391]

> We are very mindful not to shut our thoughts off completely, and that is why the first thing to do is to put in the external ventricular drain, because that is the next step, whatever your treatment is. It buys the patient time. And that was the reason why, when we sent the patient to OT, we already said we will bring the patient back immediately for another CT scan. That is to serve two purpose. Number one, to make sure the position of the EVD is there, it's draining. That's one. But the other more important reason is to look again, re-evaluate changes, especially the clot. …
>
> … the second scan we did is to make sure we have given the patient every single opportunity, and in the second scan, it clearly shows the brain stem clot has dissected all the way from pons to midbrain, to even thalamus, and if there was even the remote -- a remote doubt at the beginning, there was no such doubt at the end.

264 DW12 Dr Low's evidence was less explicit, but is consistent with, the adoption of a two-stage approach. He had stated that after EVD insertion the Second CT Scan was reviewed. From the scan it appeared that there was an

---

390 18/7/19 NE 162-164.

391 18/7/19 NE 99–100.

Version No 1: 27 Oct 2020 (22:41 hrs)

increase in size of the brainstem haematoma and so he, the First Defendant and DW11 Dr Pang went to inform the Plaintiff's family about the prognosis.[392]

265 The First Defendant's evidence, when taken alone, may suggest that a two-stage approach might not have been at the forefront of his mind. However, his actions spoke louder than his words. It is significant that it was only after he read the Second CT Scan that he went to talk to the Plaintiff's family and informed them of the Plaintiff's prognosis. He advised that EVD insertion was the only option. The fact that he had considered and ruled out alternative modes of intervention is clear from the evidence of DW5 Dr Yang Ming. In taking consent for the Second Surgery, DW5 Dr Yang Ming explained to the Plaintiff's family the need to insert the EVD. He did not inform them of the option of evacuating the haematoma as the surgical team decided against it. Crucially, *removal of the bone flap was mentioned albeit not in detail*.[393] Had the team not discussed the available options, there would have been no reason for DW5 Dr Yang Ming to raise the possibility of removing the bone flap to the Plaintiff's family of his own accord. Taking the evidence in totality and on a balance of probabilities, I find that the First Defendant must have had a discussion with DW12 Dr Low and DW11 Dr Pang, weighed the pros and cons, and made a final decision – around 2013 hrs and after looking at the Second CT Scan – that no further intervention was justified (beyond the EVD that had already been inserted). This is consistent with the two-stage approach that PW3 Dr Gan found acceptable.

---

392 DW12 Dr Low's AEIC at para 20.

393 12/7/19 NE 37.

Version No 1: 27 Oct 2020 (22:41 hrs)

266 Accordingly, the First Defendant was not negligent in only inserting an EVD, which ultimately saved the Plaintiff's life as seen from how she remains a patient at NUH, albeit in a PVS, to date. At that time, the First Defendant and his team did not know, and did not have the luxury of time to discuss, the cause of the haemorrhage as the Plaintiff was on the verge of death with Cushing reflex and bilateral pinpoint pupils. It is undisputed that without intervention, the Plaintiff would have died. The insertion of the EVD released some of the pressure in the posterior cranial fossa and saved the Plaintiff's life. Conversely, the failure to evacuate the haematoma would not have prevented the Plaintiff from being in a PVS. The haemorrhage, whatever may be the cause, was not the result of the negligence of the Defendants. This haemorrhage originated from the First Surgery in which the Plaintiff is not alleging that the Defendants were negligent. At 1829 hrs the haemorrhage had reached a critical stage and put the Plaintiff in a situation of life and death. It had already caused severe and irreversible damage to the brainstem, which also suffered haemorrhage. Hence, the First Defendant cannot be blamed for not evacuating the haematoma since this would not have made a difference to the Plaintiff's PVS.

Case B: Entirely extra-axial haematoma

(1) The Plaintiff's prognosis

267 If, contrary to my findings, the haematoma was entirely extra-axial, the Plaintiff argues that her prognosis would have been good if swift action had been taken to evacuate the extra-axial haematoma. The Plaintiff's experts highlighted several articles, including the American Heart Association and American Stroke Association's Guidelines for the management of spontaneous

Version No 1: 27 Oct 2020 (22:41 hrs)

intracerebral haemorrhage ("the AHA Guidelines"),[394] for the proposition that the failure to evacuate the haematoma would lead to a self-fulfilling prophecy of a poor outcome when the outcome would otherwise have been good. Furthermore, surgical evacuation was necessary because treatment through EVD insertion alone was dangerous. That entailed the risk of upward herniation, which could lead to haemorrhage and then death.[395] The Plaintiff cited, amongst others, an article by Roberto Heros ("the Heros article").[396] The Heros article reported that nine patients who were treated with ventricular drainage alone died and upward herniation was noted, whilst nine out of fourteen patients who were treated with surgical evacuation had good outcomes.

268 Preliminarily, I do not find the AHA Guidelines or the Heros article to be relevant to the Plaintiff's case. PW5 Dr Tang opined that the AHA Guidelines were relevant as they still dealt with haemorrhage in the posterior fossa outside the brainstem, with effects being similar to a haematoma that develops after a huge acoustic neuroma surgery.[397] DW3 Dr Hong disagreed.[398] The AHA Guidelines and the Heros article dealt with stroke or spontaneous cerebellar haemorrhages, for which the management and risks involved were different. I have already set out DW3 Dr Hong's explanation above, which is logical and convincing by the *Bolam-Bolitho* standard. Hence, I do not place much weight on the AHA Guidelines and Heros article.

---

394 PW5 Dr Tang's AEIC at p 259.

395 PCS at para 195.

396 PW5 Dr Tang's AEIC at p 215.

397 10/5/19 NE 168-169.

398 10/7/19 NE 25-28.

Version No 1: 27 Oct 2020 (22:41 hrs)

269 Turning then to the experts' evidence, DW3 Dr Hong's view was that assuming the bleed is entirely extra-axial "[i]f there was no bleeding in the brain stem and the patient was not quite so bad", then removing the extra-axial haematoma was the preferred and most recommended treatment of choice.[399] By "not so bad" he meant GCS 11 or 12 and deteriorating.[400] He emphasised that a patient would tend to do very badly if the haematoma were large *or* the patient were in a poor neurological condition.[401] This was in line with the First Defendant's opinion, which was that if the haematoma was entirely extra-axial and the Plaintiff was in a reasonable neurological state of GCS 7 to 10, he would have evacuated the haematoma.[402]

270 PW3 Dr Gan's view was more nuanced. He opined that generally speaking, for an extra-axial haematoma, if a patient's neurological condition was poor then on a balance of probabilities evacuation would be unlikely to improve the patient's neurological state. *However*, an important consideration was *how fast* and *for how long* the patient had been deteriorating.[403] Even if GCS were 4, he would still evacuate the haematoma considering the rate of deterioration, albeit that the chances of preserving neurological status would be lower.[404]

271 Assuming the haematoma was entirely extra-axial, the Plaintiff's clinical condition at 1850 hrs was GCS 3 to 4 and it could not be gainsaid that

---

399 8/7/19 NE 229

400 8/7/19 NE 230.

401 8/7/19 NE 230; 9/7/19 NE 119.

402 14/5/19 NE 153.

403 25/4/19 NE 89.

404 25/4/19 NE 91-93.

Version No 1: 27 Oct 2020 (22:41 hrs)

she was on the verge of death. She was extremely fragile and it would be defensible to conclude that she might not withstand the vigour of a more intrusive surgery of evacuating the extra-axial haematoma.

(2) My assessment of the First Defendant's approach to treatment

272 The next issue is whether the risk-benefit calculus meant that considering the available alternatives, inserting an EVD as the sole surgical response was unacceptable. The Plaintiff's counsel's contention rests on two premises: (i) that the Plaintiff's prognosis was good given the extra-axial haematoma and her rate of deterioration notwithstanding that she was in a coma with GCS 3 at 1850 hrs; and (ii) that the First Defendant should not have only inserted an EVD because he should have been alive to the risk of upward herniation, which would have arisen due to the resultant pressure imbalance (from the decanting of CSF without evacuating the extra-axial haematoma).

273 I have rejected the first proposition (at [271]). I also disagree with the second proposition. It is not clear that the risk of haemorrhage resulting from upward herniation was *an unacceptable one* that *ruled out* EVD insertion as a reasonable course of treatment.

274 DW4 Dr Ivan Ng in his report stated that EVD insertion was one of the possible treatments of the Plaintiff's condition.[405] He explained that while there was evidence of upward herniation in the aftermath of EVD insertion, upward herniation does not necessarily correspond to a worse prognosis and the outcome can go either way.[406] DW16 Dr Yu also testified that while upward

---

405 DW4 Dr Ivan Ng's AEIC, pp 57-58.

406 10/7/19 NE 139.

Version No 1: 27 Oct 2020 (22:41 hrs)

herniation can occur in the context of EVD insertion, it had already occurred before EVD insertion.[407]

275 Indeed, the evidence of the Plaintiff's own expert radiologist, PW4 Dr Pay, was that there was evidence of upward herniation before and after EVD insertion,[408] and an article he cited by Richard Cuneo *et al* stated: "The possible danger of upward herniation by ventricular drainage should be emphasized; nevertheless, upward herniation *occurred spontaneously in 75% of the cases reviewed*" [emphasis added].[409] In an article cited by PW5 Dr Tang by Sherri Braksick *et al* ("the Braksick article"), it was stated that "EVD placement should not be deferred due to a theoretical risk of clinical worsening from upward herniation".[410] The Braksick article gives the example of a patient who improved from GCS 5 to 7 after EVD insertion and worsening of upward herniation. The Plaintiff's expert PW5 Dr Tang did not comment on this aspect of the Braksick article when his attention was drawn to this article. PW2 Dr Chua went even further than Dr Pay because he attributed the upward herniation to the extra-axial haematoma. He had stated, in his report on the First CT Scan that there were "[c]hanges in keeping with transforaminal tonsillar herniation as well as ascending transtentorial herniation *from the extraaxial haematoma* in the left posterior cranial fossa" [emphasis added].[411]

276 Therefore, a surgeon cannot be negligent for EVD insertion despite the risk of upward herniation. In the end, I wish to reiterate that the *Bolam-Bolitho*

---

407 6/8/19 NE 105.

408 Dr Pay's AEIC at p 58.

409 Dr Pay's Supplemental AEIC at pp 25.

410 PW5 Dr Tang's AEIC at p 672.

411 PW2 Dr Chua's AEIC at p 15.

Version No 1: 27 Oct 2020 (22:41 hrs)

test does not require me to assess whether EVD insertion with or without evacuation is *preferable*, but only whether the First Defendant's chosen approach of inserting an EVD without evacuation is accepted by other neurosurgeons and is logical and defensible.

277 Accordingly, I find that the decision to insert an EVD as the sole surgical response would not have fallen below the standard of care, *even in Case B on the assumption that the haematoma was entirely extra-axial*. The risks of upward herniation were acceptable to a reasonable surgeon to save her life.

Allegations in relation to the Second Surgery

278 The Plaintiff alleges that before the First Defendant decided not to evacuate the haematoma, he ought to have:[412]

(a) obtained the Plaintiff's informed consent through her family members for the insertion of the post-operative EVD by fully apprising them of the purpose of the Second Surgery and the risks involved; and

(b) advised the Plaintiff's family of the consequences and risks of not evacuating the haematoma and the alternative option of evacuating the haematoma, such that they could decide if the haematoma should be evacuated.

279 I shall deal with these issues in turn.

412 SOC at paras 40(J), (K).

Version No 1: 27 Oct 2020 (22:41 hrs)

Informed consent for the Second Surgery

280 DW5 Dr Yang explained the EVD procedure to the Plaintiff's family before the EVD was inserted. DW5 Dr Yang was the one who obtained the consent from the family. He explained to them the need to insert the EVD. However, he did not inform them of the option of evacuating the haematoma as the surgical team decided against it. Removal of the bone flap was mentioned but not in detail.[413] He also did not inform the Plaintiff's family that the First Defendant would not be inserting the EVD.[414] His account is supported by the MPNs, which recorded that he spoke to the family and they were advised of the risks of general anaesthesia and the operation risks. The family understood and was agreeable. PW1 Ms Chiam signed the consent form authorising the insertion of the EVD.[415] However, she disputed the accuracy of the entries in the MPNs.[416] I am more inclined to accept the entries in the MPNs.

281 In any event, it is not a strict legal requirement, as opposed to good manners, to obtain consent from the patient's *family* where the patient is not, at that point, mentally competent to give informed consent. I do not accept the Plaintiff's counsel's argument that in getting the Plaintiff's family to sign the EVD procedure consent form there was a "voluntary assumption of responsibility".[417] Given that the Plaintiff was comatose with a GCS of 3 to 4, a doctor need only obtain her family's informed consent if there was a representative with the *legal authority* (*ie*, a deputy or a lasting power of

413 12/7/19 NE 37.

414 12/7/19 NE 36-38.

415 DBD at p 78.

416 23/4/19 NE 28-29.

417 PCS at para 252.

Version No 1: 27 Oct 2020 (22:41 hrs)

attorney) to make decisions with respect to medical treatment for the patient. The First Defendant's submission is supported by Section C6(20) of the 2016 ECEG, which provides:

> If patients have such diminished mental capacity that they cannot give consent, you must obtain consent from persons with the *legal authority* to make such decisions for them unless such persons are not contactable within reasonable time depending on the urgency of the situation. Otherwise, you must proceed according to your best judgment of the patient's best interests. [emphasis added]

282 Although the 2016 ECEG post-dates the Second Surgery, this is in substance consistent with the position at common law. In *Re T (Adult: Refusal of Medical Treatment)* [1992] 3 WLR 782 ("*Re T*"), the court stated as follows at 787:

> … There seems to be a view in the medical profession that in … emergency circumstances the next of kin should be asked to consent on behalf of the patient and that, if possible, treatment should be postponed until that consent has been obtained. *This is a misconception because the next of kin has no legal right either to consent or to refuse consent.* … [emphasis added]

283 The local case of *Re LP (adult patient: medical treatment)* [2006] 2 SLR(R) 13 is also relevant. That case involved an urgent *ex parte* application to declare that a proposed surgery to amputate both the patient's legs below the knee was lawful. The patient had no known relatives except a minor son, who was present but not legally represented. In allowing the application, the court stated at [4]:

> … Generally, a person who is sufficiently matured is entitled to give or withhold consent to any medical treatment and the doctors are entitled, if not obliged, to respect that person's decision. *No one else, however close by reason of kinship or friendship, is legally entitled to make that decision for the patient.* Where a patient is incapable of giving or withholding such consent, a third party may apply to the court under the Mental Disorders and Treatment Act … for a Committee of Person to be appointed for the purpose of acting in place of the

Version No 1: 27 Oct 2020 (22:41 hrs)

> patient and to give or withhold consent as the case may be. … [emphasis added]

284 PW1 Ms Chiam was only appointed as the Plaintiff's deputy on 18 August 2016,[418] more than two years after the Second Surgery. Since there was no one in the family with legal authority to decide for the Plaintiff at the material time, there was no corresponding obligation for the First Defendant to seek the family's informed consent before the Second Surgery. There was an emergency and immediate treatment was needed to prevent the Plaintiff's death. In such a situation, the legal significance of consent, which could not in any case have been obtained, pales in importance compared to acting in the Plaintiff's best interests, in this case assessed to be saving her life.

285 The Plaintiff's reliance on *Pang Koi Fa v Lim Djoe Phing* [1993] 2 SLR(R) 366 ("*Pang Koi Fa*") does not assist her case. The Plaintiff cites this case for the proposition that a neurosurgeon owes a duty of care to a patient's mother to avoid inflicting "nervous shock" on her.[419] But the circumstances in *Pang Koi Fa* are completely different. The entire premise of that suit was that the mother had suffered psychiatric injury that resulted in (amongst others) personality changes and suicidal tendencies. The issue was thus whether the defendant owed her a duty of care, considering the proximity of the mother's relationship to the patient (this case pre-dated *Spandeck Engineering (S) Pte Ltd v Defence Science & Technology Agency* [2007] 4 SLR(R) 100 ("*Spandeck*")). There is no allegation that the Plaintiff's family suffered nervous shock. In any case, a duty to avoid inflicting nervous shock on a patient's family differs from a duty to provide proper advice for the purposes of informed consent. The

---

418 PW1 Chiam Yu Zhu's AEIC at para 3.

419 PCS at para 251.

Version No 1: 27 Oct 2020 (22:41 hrs)

Plaintiff has not advanced her case on the footing that the *Spandeck* test is satisfied.

Option to evacuate the haematoma

286 PW1 Ms Chiam asserted that if the Plaintiff's family had been advised about the consequences and risks of not evacuating the haematoma, they would have decided to evacuate it as the Plaintiff "would have wanted to take a chance for the blood clot to be removed rather than remain in a vegetative state".[420]

287 But, as I have explained, the choice of whether to insert an EVD or to additionally evacuate the haematoma depends on the operating surgeon's philosophy. As stated by the English Court of Appeal in *R (Burke) v General Medical Council* [2005] 3 WLR 1132 at [50] and [55] (cited with approval by the UK Supreme Court in *Aintree University Hospitals NHS Foundation Trust v James* [2013] 3 WLR 1299 at [18]), a patient cannot demand that a doctor administer a treatment which the doctor considers is not warranted or is averse to the patient's clinical needs. This would apply *a fortiori* to the patient's family.

288 Such a situation should be distinguished from the reverse scenario where a doctor considers that the treatment is in the patient's best interests but the patient disagrees. As long as the patient has mental capacity, the patient is entitled to refuse the treatment pursuant to the principle of self-determination, notwithstanding the doctor's clinical judgment. This statement by Lord Donaldson of Lymington MR in the English Court of Appeal decision of *Re T* at 796–797, cited by the Court of Appeal in *ACB v Thomson Medical Pte Ltd and others* [2017] 1 SLR 918 at [116], is illustrative:

---

420 PW1 Chiam Yu Zhu's AEIC at para 85.

Version No 1: 27 Oct 2020 (22:41 hrs)

> Doctors faced with a *refusal* of consent have to give very careful and detailed consideration to the patient's capacity to decide at the time when the decision was made. …
>
> … the patient's right [to refuse consent] exists whether the reasons for making that choice are rational, irrational, unknown or even non-existent. That his choice is contrary to what is to be expected of the vast majority of adults is only relevant if there are other reasons for doubting his capacity to decide …
>
> [emphasis added]

289 In this case, the First Defendant had concluded that further intervention beyond inserting an EVD would be futile. The Plaintiff's best-case prognosis was determined by what he (reasonably, as I have found) diagnosed as a significant intra-axial pontine haemorrhage and evacuation of the extra-axial haematoma would expose the Plaintiff to further risks, including death. Thus, the First Defendant and his surgical team would not be obliged to inform the family of surgical options he would have been unwilling to carry out. In any case, the Plaintiff accepts that PW1 Ms Chiam had in fact specifically asked the First Defendant, after the Second Surgery had been carried out, whether the haematoma could be evacuated.[421] Therefore, I do not find there to have been a failure to obtain the Plaintiff's informed consent for the Second Surgery, or a failure to advise on the option of evacuating the haematoma.

Failure to perform the Second Surgery personally

290 The Second Surgery was performed by Dr Rashidul, the on-call neurosurgery registrar on 2 June 2014, under the close supervision of the First Defendant. DW12 Dr Low was also present. The procedure took around 20 minutes.

---

421 PCS at para 265; FDD at para 34(d).

Version No 1: 27 Oct 2020 (22:41 hrs)

291 Although not specifically pleaded, the Plaintiff's counsel alleged during cross-examination that the First Defendant ought to have performed the Second Surgery personally. The Plaintiff was a Class B1 private paying patient who was entitled to have the doctor of her choice to operate on her. Further, as a private paying patient, the First Defendant would directly receive a proportion of the fees of the Second Surgery, under what is known as the "preferential fee scheme".[422] The Plaintiff's counsel also highlighted Section C6(5) of the 2016 ECEG, which states:

> If patients consent to you performing any test, treatment or procedure under anaesthesia, you must not engage other persons to carry out the procedures on your behalf, or support your performance in a material way (excepting routine assistant surgeons), without patients' knowledge, unless it is an urgent or emergency situation.

292 I do not accept the Plaintiff's counsel's arguments. Firstly, the First Defendant explained that Dr Rashidul had performed the Second Surgery as it was a simple procedure and it was necessary, in a teaching hospital like NUH, to provide learning opportunities to the junior surgeons.[423] Furthermore, I agree that this practice is reasonable in the light of the team-based care practised in NUH. The First Defendant's evidence that EVD insertion was a simple procedure which a resident learns in his first year was not contradicted by the Plaintiff's experts.

293 Secondly, it does not matter that the Plaintiff was a private paying patient, as the fact remains that the First Defendant and DW12 Dr Low, a visiting associate consultant at NUH at that time, were closely supervising

---

422 21/5/19 NE 87.

423 21/5/19 NE 88.

Version No 1: 27 Oct 2020 (22:41 hrs)

Dr Rashidul throughout the entire procedure. They would intervene in the Second Surgery, if necessary. It would be different if the First Defendant was completely uninvolved in the Second Surgery. In this regard, Section C6(5) of the 2016 ECEG must be interpreted in context. The First Defendant agreed to remove the tumour and he did so. The Second Surgery was in a sense supplemental or consequential to the First Surgery. It is a simple procedure and the lead surgeon was still actively involved in the procedure by taking on a supervisory role and he was closely observing Dr Rashidul's insertion of the EVD. Therefore, I am unable to agree with the Plaintiff's contention in this regard.

Conclusion on negligence alleged at the post-operative stage

294 To summarise, the Plaintiff has failed on a balance of probabilities to show that the Defendants were negligent at the post-operative stage, for the following reasons:

(a) The Defendants were not negligent in carrying out the post-operative monitoring of the Plaintiff. The mere failure to record all the Plaintiff's neurological parameters in one document (although it will be a good practice to record all neurological observations in the NOC) was not *ipso facto* negligence. The hourly monitoring was adequate. On the whole, the standard of post-operative care of the Plaintiff was adequate notwithstanding the missing entry at 1610 hrs. At 1655 hrs when the Plaintiff's clinical condition declined with right hemiplegia, DW14 Nurse Lee alerted a doctor to attend to her. Subsequently, DW15 Dr Lu and DW5 Dr Yang arrived around 1730 hrs to attend to the Plaintiff. Her condition had improved and GCS score had improved from 13 to full score of 15 and she no longer suffered right hemiplegia. Thus, the

Version No 1: 27 Oct 2020 (22:41 hrs)

doctors' decision to monitor the Plaintiff instead of sending her for a CT scan at 1730 hrs was justified.

(b) When the Plaintiff's clinical condition took a precipitous turn for the worse at about 1820 hrs (when her GCS dropped to 10 with Cushing reflex) the Plaintiff was rushed for a CT scan. The First Defendant and his surgical team were not negligent in their interpretation of the First CT Scan. They came to the unanimous conclusion that the Plaintiff had intra-axial pontine haemorrhage in addition to extra-axial haematoma in the posterior cranial fossa. The prognosis of the Plaintiff was very poor. The First Defendant's surgical team's diagnosis that the Plaintiff had intra-axial pontine haemorrhage before the Second Surgery was supported by the Defendants' neurological experts, whose opinions were convincing and logical. I also accept the Defendants' witnesses' opinions that the Plaintiff's pons had rebounded, although not entirely, into the tumour cavity. This was a fundamental and necessary premise for the interpretation that some of the haematoma in the tumour cavity was intra-axial. There was pontine haemorrhage and this was verified by the Plaintiff's clinical presentation (*ie*, her GCS was 3 to 4 (deep coma) and she had Cushing reflex), and the radiological features on the First CT Scan. Hence, the First Defendant's diagnosis satisfied the *Bolam-Bolitho test.*

(c) The First Defendant and his surgical team were not negligent in deciding to insert an EVD without taking the additional step of evacuating the haematoma. This treatment was consistent with PW3 Dr Gan's two-step approach. The Plaintiff's clinical condition was very poor as there was an intra-axial pontine haematoma. The risks of evacuating the extra-axial haematoma were significant and life

Version No 1: 27 Oct 2020 (22:41 hrs)

threatening while the benefits were minimal, in view of the poor prognosis attributable to the intra-axial haematoma, which all the experts accepted should not be removed. The decision not to evacuate the extra-axial haematoma has also satisfied the *Bolam-Bolitho test.*

(d) With regard to the issue of obtaining consent for the Second Surgery, the Defendants were not negligent. They had obtained the Plaintiff's informed consent through PW1 Ms Chiam for the insertion of the post-operative EVD by sufficiently apprising her and the Plaintiff's family members of the purpose of the Second Surgery and the risks involved. The First Defendant also advised against the evacuation of the extra-axial haematoma.

Causation

295 Given my findings above that the Defendants were not negligent, this would be sufficient for me to dismiss the Plaintiff's case. However, for completeness I am of the view that the Plaintiff also would not have succeeded on causation even if (contrary to my findings above) the Defendants had been negligent.

296 The Plaintiff's case is that the Defendants' series of missteps caused or materially contributed to her PVS:[424]

(a) If the Plaintiff's relevant neurological parameters had been recorded properly at 1610 hrs, her progressive right-sided weakness would "in all likelihood have been picked up" before 1655 hrs when she

[424] PCS at paras 4, 241.

Version No 1: 27 Oct 2020 (22:41 hrs)

had right hemiplegia. This would "in all likelihood" have resulted in further investigations by way of a CT scan.[425]

(b) If the Second Defendant had monitored the Plaintiff's condition diligently and carried out a CT scan at 1655 hours, the CT scan would have likely shown the presence of a sizeable extra-axial haematoma "that was more manageable than the one seen at 1829 [hrs], making her an ideal candidate to have the haematoma evacuation".

(c) Even if a CT scan was done only at 1730 hrs, the same analysis would apply and there would have been a "more than even chance" that the brainstem compression from the extra-axial haematoma could have been addressed without leaving the Plaintiff in a PVS.

(d) If the haematoma had been detected when it was of a smaller size and when the Plaintiff's GCS was still good, the First Defendant would not have misdiagnosed the haematoma as being substantially intra-axial.

(e) If the First Defendant had diagnosed the haematoma as being substantially extra-axial, he would have evacuated the haematoma at 1829 hrs. At that point, the Plaintiff's condition was still reversible and she had a good chance of avoiding PVS, even if she might have had neurological deficits.

(f) If the Defendants had properly advised the Plaintiff's family on the alternative of evacuating the haematoma, "it is likely that [the

425 PCS at para 77.

Version No 1: 27 Oct 2020 (22:41 hrs)

> Plaintiff's] family would have taken the option of surgical evacuation ... no matter how slim the chances of functional recovery".[426]

297 The Plaintiff also raises the loss of chance argument for the above.

298 Preliminarily, the Plaintiff appears to have treated but-for causation, material contribution to damage and loss of chance as interchangeable. That approach is incorrect.

(a) A plaintiff must establish causation in fact and in law in a negligence claim (Gary Chan, *The Law of Torts in Singapore* (Academy Publishing, 2nd Ed, 2016) ("*Law of Torts in Singapore*") at para 07.011).

(b) Causation in fact usually refers to the "but for" test, which considers whether the injury would not have been suffered "but for" the defendant's negligence: *Sunny Metal & Engineering Pte Ltd v Ng Khim Ming Eric* [2007] 3 SLR(R) 782 at [71]. The operation of the but-for test is illustrated in *BNM (administratrix of the estate of B, deceased) on her own behalf and on behalf of others v National University of Singapore and others and another appeal* [2014] 4 SLR 931 ("*BNM*"). The deceased's estate sued NUS for negligence following his drowning in a swimming pool owned by NUS. The court held that causation was not established. Even if the lifeguards had administered CPR later than they should have, CPR alone would not have saved the deceased because he had an underlying heart condition that would have, in the circumstances of the drowning, necessitated the use of defibrillation by an automated external defibrillator ("AED") to give him a fighting chance at survival

426 PCS at para 265.

Version No 1: 27 Oct 2020 (22:41 hrs)

(*BNM* at [61]–[66]). Since the failure to provide an AED was not a breach of duty, the deceased's death was not caused by any act of negligence attributable to NUS.

(c) In some circumstances, however, instead of proving that the injury would not have occurred but for the defendant's breach, it suffices for the plaintiff to show on a balance of probabilities that the defendant's breach materially contributed to the damage. The material contribution to damage test applies where the same injury, which is typically accretive or cumulative in nature, could have resulted from multiple causes. The classic situation is that in *Bonnington Castings Ltd v Wardlaw* [1956] 2 WLR 707, where the plaintiff's employee was exposed to silicone dust from both tortious and non-tortious sources. There was no evidence on the proportion of each source of dust, but it was established that the employee had suffered from pneumoconiosis and the severity of the illness was in proportion to the level of exposure. The plaintiff was awarded full damages because the defendant's failure to install an effective safety measure "materially contributed to the disease" (at 712).

(d) It is also possible for a plaintiff to argue on the basis of loss of chance. In such a situation, the plaintiff is claiming that he has lost the chance of a benefit or avoiding a loss as a result of the defendant's negligence. Hence, instead of an "all or nothing" approach, the plaintiff is claiming for a proportion of the damages" (*Law of Torts in Singapore* at para 06-047). The figures for loss of chance do not relate to the possibility of recovery for the actual individual plaintiff, but is a measure of the possibility of recovery of a hypothetical sample of persons who are assumed to have suffered the injury in question. A plaintiff must

Version No 1: 27 Oct 2020 (22:41 hrs)

show that the loss of chance is above 50%: *Law of Torts in Singapore* at para 06-050.

299 As seen from the above, the material contribution to damage test would *not* apply to the allegations regarding the failure to monitor, the CT scans and the failure to advise on the option of evacuating the haematoma (at [296(a)]–[296(d)] and [296(f)]) because those are not situations whereby the damage is cumulative from multiple causes or tortious agents. In respect of these allegations the Plaintiff may only proceed on the basis of but-for causation or loss of chance. Not so for the allegation at [296(e)]. A material contribution to damage analysis can potentially apply *if* the Plaintiff can prove that the brain haemorrhage which caused the PVS is cumulative in nature and can arise from multiple causes. In this regard the First Defendant is incorrect in contending that the *only* way for the Plaintiff to succeed is to prove but-for causation.[427]

Omission to record neurological parameters at 1610 hrs

300 The Plaintiff has not satisfied either the but-for test or the loss of chance standard, as she has not shown that the omission to monitor or record all her parameters in the NOC at 1610 hrs resulted in any demonstrable damage or even consequences for her.

301 The Plaintiff's position is that the failure to conduct hourly monitoring resulted in no parameters being taken at 1610 hrs. The parameters, if taken, may well have shown signs of deterioration such as limb weakness or changes in pupil size which in turn would show the extra-axial haemorrhage, being

---

427 DC1S at para 345.

Version No 1: 27 Oct 2020 (22:41 hrs)

discovered at an earlier stage, at a more manageable size.[428] This is too speculative. As DW3 Dr Hong pointed out, neurological state fluctuates. At 1655 hrs the Plaintiff had right hemiplegia but at 1730 hrs she had some limb movement.[429] It may well be that at 1610 hrs the Plaintiff's neurological parameters (in particular, limb power) were normal as she was GCS 15 at 1605 hrs. Thus, it is impossible to conclude that the opportunity to pick up earlier deterioration in the Plaintiff was lost because the relevant neurological parameters were not charted at 1610 hrs.

Not ordering a CT scan at 1655 hrs or 1730 hrs

302 Similarly, the Plaintiff has not satisfied either the but-for test or the loss of chance standard here.

303 Even assuming a CT scan was ordered between 1655 hrs and 1730 hrs, it is speculative what that scan would have shown. I analyse these two timings together because in the analysis of this hypothetical scenario we have to take into account the time for DW14 Nurse Lee to review the Plaintiff's GCS and motor strength as well as the time taken to bring her to the Department of Diagnostic Imaging to have the CT scan done. By the time all these were completed it would have been probably close to 1730 hrs in which the Plaintiff's condition had improved substantially.

304 The Plaintiff's case was that if a CT scan had been done at 1655 hrs, "it would have shown a smaller, actively-growing haematoma".[430] PW3 Dr Gan,

---

428 PCS at para 77.

429 8/7/19 NE 188.

430 PCS at para 126.

Version No 1: 27 Oct 2020 (22:41 hrs)

PW5 Dr Tang, and DW4 Dr Ivan Ng testified that a scan at 1655 hrs would likely have shown a smaller haematoma.[431] But none of them testified as to whether this haematoma would have been intra-axial, extra-axial or both. Further, it is significant that DW3 Dr Hong and DW4 Dr Ivan Ng also testified that the key factor determining the course of patient management would be the patient's neurological state. Both would not evacuate any haematoma shown on a scan at 1655 hrs *as long as the Plaintiff was alert* (*ie*, with a good GCS score of 14–15).[432] The process of removing the haematoma has its risks, such as damage to the cranial nerves and removal of healthy brain tissue, as well as the risk of death to the Plaintiff. These risks would outweigh the benefits, especially considering how haematomas can resolve and pose no danger to the Plaintiff, albeit over time.[433] The risk-benefit calculus would differ if a patient were drowsy as the surgeon would then be going in there to save the patient's life, but such was not the case, as seen from the documented GCS scores. It must be recalled that when DW15 Dr Lu reviewed the Plaintiff at 1730 hrs, he recorded a GCS of 15 and that she was alert and moving all four limbs.

305 Thus, even if a CT scan had been done at between 1655 hrs and 1730 hrs, the Plaintiff could not show demonstrable damage had been done to her or that she had lost a chance of a course of treatment with better results. It is simply too speculative what the scans might have shown. It is also incorrect to assume that surgical intervention would necessarily have been ordered or that it was even appropriate, even if what would have appeared on the scan was a smaller extra-axial haematoma. This speculative assumption has to be considered in the

---

431 26/4/19 NE 169; 10/7/19 NE 182, 203; 7/5/19 NE 22-23.

432 8/7/19 NE 60–61; 09/7/19 NE 160.

433 8/7/19 NE 183; 10/07/19 NE 18.

Version No 1: 27 Oct 2020 (22:41 hrs)

light of the Plaintiff's GCS 15 at 1605 hrs and 1620 hrs and the fact that haematomas may resolve on their own as DW3 Dr Hong testified.[434]

Failure to advise on the option of evacuating the haematoma

306 The Plaintiff has not shown that her family would have chosen to evacuate the haematoma but for the fact that they were not given this option, or that there was a real or substantial chance that her family members would have opted to evacuate the haematoma.

307 The Plaintiff relies on the fact that PW1 Ms Chiam had specifically asked the First Defendant if the Plaintiff's haematoma could be evacuated after the Second Surgery had been carried out, and "on the basis of PW1 Ms Chiam's demeanour in court", to argue that the Plaintiff's family would have chosen to have the haematoma evacuated.[435] I do not find these to be sufficient. On the contrary, if the Plaintiff's family were told that the evacuation of the haematoma carried with it a very high risk of death to the Plaintiff who would very likely remain PVS, I believe they would not want to risk killing the Plaintiff as their love for their mother is evident in the trial. In any case this is speculative.

Failure to evacuate the extra-axial component of the haematoma

308 I have explained why the Defendants were not negligent when the First Defendant and his surgical team did not remove the extra-axial haematoma at the Second Surgery. This would be sufficient to dismiss the Plaintiff's claim for post-operative negligence in respect of the First Surgery. However, for completeness, I shall proceed to consider whether the Plaintiff would have

434 8/7/19 NE 183.

435 PCS at para 264-265.

Version No 1: 27 Oct 2020 (22:41 hrs)

proven causation on the but-for or material contribution to damage standards in Case A.

309 If the failure to remove *the extra-axial haematoma in the surgical tract* fell below the standard of care, did the Plaintiff end up in a PVS *because* the First Defendant did not evacuate the extra-axial haematoma? There is no conclusive evidence to show that the Plaintiff would not have ended up in a PVS but for the First Defendant's failure to evacuate the extra-axial haematoma that existed in the surgical tract at 1829 hrs. Her experts were speculative in her chances of improving her functionalities. They preferred to take these chances over the high possibility of death. Regardless of the surgical intervention the First Defendant decided upon, the ultimate determinant of her outcome was the existence of the intra-axial haematoma in the pons, which was already present and had caused damage *before* the First Defendant could act. She had *already* hit rock bottom (leaving aside the possibility of death) with the intra-axial pontine haematoma at 1829 hrs. Therefore, causation has not been made out and the Plaintiff's claim cannot succeed as the Plaintiff's state of PVS was not due to the First Defendant's failure to remove the extra-axial haematoma in the surgical tract. I reiterate that the Plaintiff does not allege that the First Defendant and his surgical team was negligent at the First Surgery. Therefore, the Plaintiff would not have proven causation in any event.

Alternative causation analysis for evacuation of haematoma if the haematoma had been entirely or substantially extra-axial

310 I address this alternative scenario (Case B) only because substantial time and effort was spent addressing this in the course of trial and in closing submissions.

Version No 1: 27 Oct 2020 (22:41 hrs)

311 If the haematoma in the posterior cranial fossa was entirely extra-axial at 1829 hrs, the Plaintiff contends that her prognosis *at that point* was good. It was only when the First Defendant decided to insert an EVD without also evacuating the extra-axial haematoma, that there was a pressure imbalance that resulted in upward herniation of the brainstem, which caused the brainstem, midbrain and thalamus to haemorrhage. Ultimately, this led to her current dire condition of being in a PVS ("upward herniation theory"). The images below, taken respectively from the First CT Scan, Second CT Scan and third CT scan on 3 June 2014 ("Third CT Scan") show the enlarging areas of haemorrhage in the abovementioned regions of the brain over time. I shall refer to these as the "new haemorrhages".

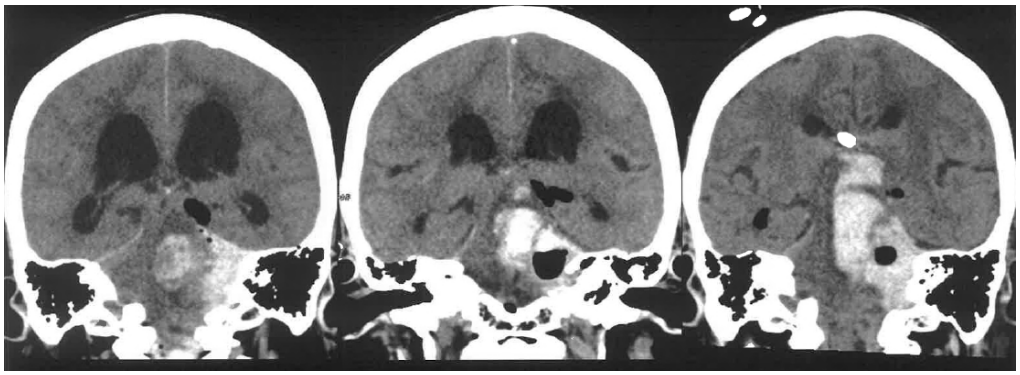

Coronal views from the First, Second and Third CT Scans (from left to right).

312 The First Defendant contends that even if the haematoma in the tumour cavity was entirely extra-axial, the failure to remove this haematoma did not cause the Plaintiff to end up in a PVS. The Plaintiff had suffered a venous infarct in her brainstem, which could ultimately lead to haemorrhage in her brainstem and cause a PVS even if the extra-axial haematoma was evacuated.[436]

436 FDD at para 38.

Version No 1: 27 Oct 2020 (22:41 hrs)

Alternatively, she had suffered oedema or venous congestion in her brainstem which would have caused brainstem haemorrhage and led to her PVS, even if the extra-axial haematoma was evacuated.[437]

313 The key issue is thus whether the new haemorrhages were caused by upward herniation as the Plaintiff contends, or by a venous infarct as the Defendants contend, or both.

Upward herniation theory

314 All of the Plaintiff's experts supported the upward herniation theory: the insertion of the EVD reduced the pressure in the supratentorial region. This caused a pressure imbalance because infratentorial pressure was still high, resulting in the brainstem moving *upward* through the tentorial notch. The movement of the brainstem caused the perforating arteries to tear and thus the increase in petechial haemorrhages, in a similar mechanism to Duret haemorrhages (though Duret haemorrhages classically describe downward herniation).[438]

315 The Defendants took issue with the upward herniation theory in several respects. First, the First Defendant doubted whether the mechanism postulated by the Plaintiff could explain the injuries suffered. He explained that the arteries were tethered in a way that in the brainstem would result in Duret haemorrhage only when there was *downward* herniation.[439] The First Defendant's opinion is

---

437 FDD at para 39.

438 24/4/19 NE 84, 88-89; PBD2 at slides 35, 40, 47; PW3 Dr Gan's AEIC at p 41; 7/5/19 NE 98-100; 9/5/19 NE 59-60, 64; Dr Pay's AEIC p 14; PBD4 at slide 40; 2/5/19 NE 81.

439 21/5/19 NE 67.

Version No 1: 27 Oct 2020 (22:41 hrs)

that because of the structure of the brainstem relative to the blood vessels, upward herniation would not cause Duret haemorrhage. DW16 Dr Yu also opined that the location of Duret haemorrhages is usually in the midbrain and sometimes in the pons and medulla, but in the Plaintiff's case there was haemorrhage in the thalamus which was unusual for Duret haemorrhage.[440] In fact, because the thalamus is above the midbrain, if there is upward herniation the arteries going from the basilar artery to the thalamus would actually be closer together and *not* stretched (such that they would shear and tear).[441] However, I am not prepared to discount the upward herniation theory on this basis because DW3 Dr Hong did opine that it was theoretically possible that some damage might be caused to the brainstem and blood vessels with substantial upward herniation.[442] This view is logical given the nature of the structures in the brain, though the damage might, perhaps, not be as severe or wide-ranging as the Plaintiff alleges.

316 Secondly, the First Defendant contends that it was not only the EVD insertion but also swelling and/or haemorrhage within the posterior cranial fossa that led to upward and downward herniation.[443] This was also the view of DW3 Dr Hong, DW16 Dr Yu and DW10 Dr Yeh, who opined that upward herniation was attributable not only to the EVD but also progressive enlargement of the haematoma, causing the brain structures to swell upwards.[444] However, DW10 Dr Yeh explained that this view was based on the assumption that the bulk of

---

440 D2CS at para 191.

441 5/8/19 NE 73.

442 8/7/19 NE 73–74; 9/7/19 NE 214–215; 21/5/19 NE 67.

443 21/5/19 NE 61.

444 17/7/19 NE 86; 9/7/19 NE 206; 6/8/19 NE 104.

Version No 1: 27 Oct 2020 (22:41 hrs)

the haematoma was intra-axial. If the haematoma was mainly extra-axial in the tumour cavity, then any haemorrhage into the brainstem and/or petechial haemorrhage alone would not suffice to cause upward herniation.[445]

317 Thirdly, the First Defendant considers that it would be highly unlikely for an extra-axial haematoma to be able to cross the brainstem barrier (*ie* the pia matter). However, he states that he maintained an open mind,[446] and in any case, the possibility of dissection is supported not only by most of the Plaintiff's experts but also DW4 Dr Ivan Ng.

318 Therefore, it is reasonable to accept that there would be some upward herniation of the brainstem after the EVD was inserted and that this would cause some degree of fresh haemorrhage in the midbrain and thalamus (*ie*, the new haemorrhages).

Venous infarct theory

319 The First Defendant explains that there was venous infarct arising from SPV ligation during the First Surgery, which had begun before 1829 hrs and progressively worsened.[447] The mechanism of an infarct is as follows. Although most patients can tolerate SPV sacrifice, the Plaintiff had atypical venous anatomy and lacked sufficient venous collateral channels for incoming blood to flow out after SPV sacrifice. Consequently, following SPV sacrifice there was congestion and fluid accumulation in the interstitial spaces between cells, leading to swelling (vasogenic oedema) and pressure build-up. When pressure

445 19/7/19 NE 248-249.

446 14/5/19 NE 180-181.

447 Dr Yeo's AEIC at paras 79, 106, 111.

Version No 1: 27 Oct 2020 (22:41 hrs)

exceeded that of the small arteries supplying the brain, blood supply to the brain tissue was cut off and tissue death (infarction) occurred. Cell death caused even more swelling (cytotoxic oedema) and further increases in pressure. While all this was ongoing, the increase in pressure caused the thin-walled small veins (venule) to burst, leading to haemorrhage.[448] DW3 Dr Hong[449] and DW10 Dr Yeh[450] agreed with the venous infarct theory. DW16 Dr Yu also agreed that venous infarct was an "important consideration".[451]

320 The Plaintiff's counsel submits that the venous infarct theory was a "belated afterthought" that deviated from the Defendants' experts' original position on the cause of the haemorrhage, and the Defendants' case that the intra-axial haemorrhage had resulted from an extra-axial haemorrhage extending into the brainstem.[452] The Plaintiff's counsel also points out a contradiction in the Defendants' case when the First Defendant stated that an extra-axial haemorrhage could not dissect into the brainstem.[453]

321 The Plaintiff's counsel attacks the venous infarct theory on several grounds. Firstly, PW5 Dr Tang pointed out that there was no sign of an arteriovenous malformation ("AVM") (*ie*, abnormality at the junction where arteries connect to the veins) on the Plaintiff's RadLink MRI scan.[454] An AVM was present in the case described in the article written by Giulio Anichini *et al*

---

448 14/5/19 NE 98-103; 16.05.19/136.

449 8/7/19 NE 67.

450 1D16 at slide 73.

451 5/8/19 NE 109-110.

452 PCS at paras 274-290.

453 Dr Yeo's AEIC at para 50.

454 9/5/19 NE 95.

Version No 1: 27 Oct 2020 (22:41 hrs)

relied on by the First Defendant for his venous infarct theory ("the Anichini article"). However, DW16 Dr Yu explained that while a large AVM might be visible even on an unenhanced CT scan, usually this would require a contrast-enhanced scan to diagnose or even an angiogram to fully exclude that possibility. An angiogram would involve injecting directly into an artery to check for opacification.[455] This was not done in the Plaintiff's case so the possibility that there is an AVM cannot be ruled out. In any case, DW16 Dr Yu testified that venous infarct could occur even without an AVM present.[456]

322 Secondly, the Plaintiff's counsel contends that the pattern of the Plaintiff's deterioration did not match the timeframe that would be expected in cases of venous infarct. PW2 Dr Chua was of the view that infarction resulting from SPV ligation would appear within a five-minute period.[457] On the other hand, the First Defendant explained that the possible timeframes ranged from immediately on the operating table to as long as two days after SPV sacrifice. PW5 Dr Tang, whilst contending that the patient should generally show immediate signs of deterioration and swelling, also accepted that swelling, oedema and eventual cell death could manifest over a period of time.[458] PW4 Dr Pay eventually agreed that venous infarct could occur within minutes, hours or days.[459] DW4 Dr Ivan Ng accepted that delayed deterioration was possible, albeit that the literature suggested that this was *usually* in "other surgical

455 5/8/19 NE 169.

456 13/8/19 NE 2.

457 2/5/19 NE 33.

458 8/5/19 NE 56, 61.

459 3/5/9 NE 174-175.

Version No 1: 27 Oct 2020 (22:41 hrs)

procedures where there is no tumour involvement".[460] Therefore, the First Defendant's explanation was supported by other neurological experts. It is precisely because the Plaintiff's situation is not "run of the mill" that she did not recover despite the uneventful surgeries, leading to this lawsuit today.

323 Thirdly, the Plaintiff's counsel contends that it was difficult, if not impossible, to distinguish between oedema and infarct at the initial stages and within the timeframe that the First Defendant was working in. But even if it is difficult to ascertain whether the First CT Scan showed oedema or infarct, this does not assist the Plaintiff because causation – unlike breach of duty – can be analysed with the benefit of hindsight. In other words, there could be an *existing* cause of the Plaintiff's PVS at 1829 hrs (*ie*, the incipient infarct, which was unrelated to EVD insertion) that only becomes apparent *subsequently.* For the avoidance of doubt, the Plaintiff cannot allege that the First Defendant breached his duty by negligently diagnosing an infarct at 1829 hrs. That is factually unsupported, because the First Defendant did *not* conclude that there was infarct at that time. It was only subsequently, after (amongst others) viewing the Anichini and Nanda articles, that he put forth his venous infarct theory.[461]

324 Fourthly, PW5 Dr Tang opined that the thalamic bleeds could not have been caused by infarct because the SPV does not drain the thalamus, only the cerebellum and part of the midbrain. But DW3 Dr Hong explained that while the thalamus is not normally drained by the SPV, the veins are all interconnected and anything that causes disturbance can be transmitted through the entire

460 10/7/19 NE 134–135.

461 21/5/19 NE 28.

Version No 1: 27 Oct 2020 (22:41 hrs)

venous plexus.[462] DW16 Dr Yu took a similar view that thalamic bleeds could result from SPV ligation, citing in support the Anichini article that mentioned four major veins which drained into the SPV (those pertaining to the brainstem, the cerebellum, the thalamus and the temporal lobe).[463]

325 Fifthly, all the Plaintiff's experts opined that there was insufficient supporting evidence of infarct subsequently (on the Second CT Scan, Third CT Scan and 1 July 2014 MRI scan) to support the venous infarct theory.[464] On the other hand, DW16 Dr Yu's evidence was that the 1 July 2014 MRI scan showed evidence of infarct. DW10 Dr Yeh explained that by definition of a venous *haemorrhagic* infarct, the areas of intra-axial haematoma would overlap with, and therefore obscure, the areas of infarction.[465]

326 Sixthly, the Plaintiff's counsel contends that the haemorrhage and infarct in the Plaintiff's case did not respect the midline as the First Defendant argued.[466] This point arose because the First Defendant had explained that his venous infarct theory was supported because the dark patches on the scans were localised to one side of the brainstem, which supported the view that only the blood vessels on one side were affected (as expected of an infarct). The First Defendant's explanation was that the midline was not totally straight due to the cytotoxic oedema whereby the cells swell and cross the "true" midline.[467]

---

462 9/7/19 NE 209–210.

463 6/8/19 NE 150-151.

464 PW3 Dr Gan's Supplementary AEIC at p 7, para 2.7; PW5 Dr Tang's Supplementary AEIC at p 5, para 8; PBD4 at slide 35; PBD2 at slide 29.

465 19/7/19 NE 137.

466 PCS at paras 304-314.

467 14/5/9 NE 118-121.

Version No 1: 27 Oct 2020 (22:41 hrs)

327 Seventhly, the Plaintiff's counsel contends that the significant amount of oedema was equally attributable to the Plaintiff's deterioration before the First Surgery.[468] I have already rejected this argument about pre-existing oedema above. The Plaintiff's counsel also relies on the fact that the Plaintiff had developed symptoms of hydrocephalus between May 2014 and 2 June 2014, including weakness, drowsiness, incontinence and vomiting.[469] It is not open to the Plaintiff to now rely on these alleged symptoms as she had abandoned her claim that there was hydrocephalus which the First Defendant ought to have addressed through an EVD or a shunt before the First Surgery.

328 The Plaintiff's criticisms of the venous infarct theory are generally unconvincing. I cannot rule out that there was an incipient venous infarct before 1829 hrs arising from SPV ligation, which progressed to cause the haemorrhages. The Defendants and their experts had explained that the venous infarct started a chain reaction and caused the intra-axial pontine haemorrhage as well as the extra-axial haematoma in the surgical track and the tumour cavity. The Defendants have satisfied the *Bolam-Bolitho* test in relation to the plausibility of the venous infarct theory, as their experts have supported the venous infarct theory to explain the cause of the pontine haemorrhage and extra-axial haematoma in the posterior cranial fossa.

My assessment of the new haemorrhages

329 The reality is that the experts on both sides could not conclusively and definitely explain the cause or causes of *any* of the haemorrhages in the posterior cranial fossa, whether this refers to the haemorrhage in the posterior cranial

468 PCS at para 320.

469 PCS at para 322.

Version No 1: 27 Oct 2020 (22:41 hrs)

fossa at 1829 hrs (visible on the First CT Scan), or the new haemorrhages in areas such as the midbrain and thalamus (visible on the Second CT Scan and subsequent scans). The experts have floated various possibilities. It is also possible that the causes postulated by the Plaintiff and the Defendants could *jointly* be responsible for the new haemorrhages. For instance, DW16 Dr Yu had opined that SPV ligation, the presence of extensive oedema and petechial haemorrhage on the First CT Scan, and the subsequent extensive haemorrhage (in the left midbrain / cerebral peduncle, left thalamus and vermis), all meant that venous infarct was likely. DW16 Dr Yu further opined that the pressure of the Plaintiff's posterior cranial fossa had built up to such an extent that there was tonsillar herniation (downward herniation) resulting in Duret-like haemorrhage in the brainstem, as well as upward herniation of the brainstem.

330 The undeniable fact is that sometime after the First Surgery ended (at around 1415 hrs), a haemorrhage began in the Plaintiff's posterior cranial fossa. The haemorrhage began without any intervention or fault of the First Defendant. It progressed and initially caused, extra-axial, and subsequently, intra-axial haematoma (recalling that here I am dealing with Case B where the haematoma in the First CT Scan would be extra-axial). It is significant that even on PW2 Dr Chua's annotation of where the oedema was, the oedema encompassed the region where he drew the pons was (see [219] above). An oedematous pons would already be injured and was more likely to bleed. The haemorrhage led to the build-up of the pressure in her posterior cranial fossa and caused tonsillar herniation of the brainstem through the foramen magnum which in turn caused Duret-like haemorrhage. Eventually, the pressure also caused an upward herniation of the brainstem through the tentorium notch to the supratentorium. This was what happened at 1829 hrs and the Plaintiff's clinical condition worsened with the falling GCS. The deterioration of the Plaintiff's condition

Version No 1: 27 Oct 2020 (22:41 hrs)

continued until the Second Surgery when the EVD was inserted. Regardless of the cause(s) of the haemorrhage, there were oedema and haemorrhage. It was the haemorrhage arising from the First Surgery, where there is no allegation of negligence, that eventually resulted in the Plaintiff being in a deep coma at 1850 hrs and left her in a PVS. Thus, the Plaintiff's PVS was due to the haemorrhage arising from the First Surgery and not the negligence, if any, of the First Defendant for failure to evacuate the haematoma.

Conclusion on causation

331 To summarise, the Plaintiff has failed to establish causation for the following reasons:

(a) Regarding the omission to record the Plaintiff's parameters at 1610 hrs, the Plaintiff would not have satisfied the but-for test or the loss of chance standard as she has not shown that the omission to monitor or record all parameters in the NOC at 1610 hrs resulted in any demonstrable damage. The potential readings at 1610 hrs were simply too speculative.

(b) Similarly, the Plaintiff has not satisfied either the but-for test or the loss of chance standard in relation to the failure to order a CT scan at 1655 hrs or 1730 hrs. It is too speculative what size and location of haematoma (if at all) the CT scans at these times would have shown.

(c) The Plaintiff has not shown that her family would have chosen to have the haematoma evacuated but for the fact that they were not given the option to do so, or that there was a real or substantial chance that her family members would have opted to evacuate the haematoma.

Version No 1: 27 Oct 2020 (22:41 hrs)

(d) On Case A (pontine haematoma), the failure to evacuate the extra-axial component of the haematoma did not cause her PVS whether on a but-for or material contribution to damage standard. Regardless of the surgical intervention that the First Defendant decided upon, the ultimate determinant of her outcome was the existence of the intra-axial haematoma in the pons, which was already present and had caused damage before the First Defendant could act.

(e) On Case B (extra-axial haematoma), I could not rule out either the upward herniation theory or the venous infarct theory. It is also possible that both causes were jointly responsible for the new haemorrhages. Regardless, it was the haemorrhage arising from the First Surgery, where there is no allegation of negligence, that eventually resulted in the Plaintiff being in a deep coma at 1850 hrs and left her in a PVS. Thus, the Plaintiff's PVS was due to the haemorrhage arising from the First Surgery and not the negligence, if any, of the First Defendant for failure to evacuate the haematoma.

Fracture suffered by the Plaintiff

332 The Plaintiff argues, relying on the doctrine of *res ipsa loquitur*, that the Second Defendant was negligent by causing her to suffer a fracture while she was in NUH's care. In August 2016, PW1 Ms Chiam requested an X-ray for the Plaintiff.[470] An X-ray done on 19 August 2016 revealed that the Plaintiff was suffering from a mild displaced fracture at the right tibial tuberosity,

470 PW1 Chiam Yu Zhu's AEIC at para 102.

Version No 1: 27 Oct 2020 (22:41 hrs)

degenerative changes of the right knee joint and diffuse osteopaenia of the imaged bones.[471]

333 *Res ipsa loquitur* is a rule of evidence that enables a plaintiff to establish a *prima facie* case of negligence if there is insufficient direct evidence to establish the cause of the accident in a situation where the accident would not have occurred in the ordinary course of things had proper care been exercised: *Grace Electrical Engineering Pte Ltd v Te Deum Engineering Pte Ltd* [2018] 1 SLR 76 ("*Grace Electrical Engineering*") at [39]. The requirements for the doctrine to apply are stated in *Rathanamalah d/o Shunmugam v Chia Kok Hoong* [2018] 4 SLR 159 ("*Rathanamalah*") at [106]:

> (a) the occurrence is such that it would not have happened without negligence;
>
> (b) the thing which inflicted the damage was under the sole management and control of the defendant; and
>
> (c) there is no evidence as to why or how the occurrence took place.

Once the three requirements are satisfied, the defendant must adduce evidence to rebut the *prima facie* case of negligence. This is because the injury may then itself be taken as evidence of the defendant's failure to take reasonable care, on the balance of probabilities. If the defendant can provide a plausible explanation of what happened, consistent with the exercise of due care, the claim will fail (*Grace Electrical Engineering* at [39]–[40]; *Rathanamalah* at [106]–[107]).

---

471 DW8 Prof Shamal Das De's AEIC at para 4.

Version No 1: 27 Oct 2020 (22:41 hrs)

334 *Res ipsa loquitur* has been invoked in medical negligence cases. In *Cassidy v Ministry of Health* [1951] 2 KB 343, the plaintiff was warded for an operation on his left hand to correct a contraction of his third and fourth fingers. Post-operatively, his hand and arm were kept rigid in a splint for eight to 14 days. During this period he was under the care of the hospital's nursing staff. After that treatment, it turned out his hand had been rendered useless. The court held that *res ipsa loquitur* applied. Similarly, in *Mahon v Osborne* [1939] 2 KB 14, the court by a majority held that the principle applied in circumstances where a surgeon had left a swab in the patient's abdomen after an operation and the patient died three months afterwards.

335 The only pertinent issue here is whether requirement (a) is met. It is not disputed that the cause of the Plaintiff's fracture is unknown. The evidence of DW8 Prof Shamal Das De ("DW8 Prof Shamal"), the orthopaedic surgeon, who saw the Plaintiff after the injury was discovered, was that he could not ascertain the cause of the fracture or when it occurred. The 19 August 2016 X-ray, showed an old small fracture and was already healing.[472] He noted bruising over the posteromedial aspect of the knee that he described as "old" and estimated as dating back a few weeks.[473] Nor is it seriously disputed that the Plaintiff was under the care of the Second Defendant's personnel throughout her time at NUH, including when she was sent for various deep vein thrombosis scans pursuant to PW1 Ms Chiam's complaints of discoloration and swelling on the Plaintiff's limbs before the 19 August 2016 X-ray.

---

472 DW8 Prof Shamal Das De's AEIC at para 11.

473 16/7/19 NE 96.

Version No 1: 27 Oct 2020 (22:41 hrs)

336 I find that *res ipsa loquitur* is not made out as requirement (a) is not satisfied on a balance of probabilities. In other words, the Plaintiff failed to show that the fracture of the Plaintiff's tibial tuberosity must only be the result of the Second Defendant's negligence. It is undisputed that the Plaintiff was warded at NUH since the First Surgery. However, the management of the Plaintiff was done jointly by the Second Defendant and the Plaintiff's family. There are two possible scenarios in which the fracture could have occurred. It could have arisen as a result of the mishandling or accidental handling by NUH staff, or it was due to mishandling or accidental handling by the Plaintiff's family when they repositioned her (it is not disputed that they visited her routinely). The Plaintiff has the burden of proving that *res ipsa loquitur* applies. PW1 Ms Chiam did not testify that the family did not, when they visited her, move or reposition the Plaintiff in any way. It must be borne in mind that this is an injury arising from moving the Plaintiff. DW8 Prof Shamal testified that the fracture was a partial avulsion fracture, *ie*, a partial crack of the largest part of the tibia that is nearest the kneecap, due to the pulling or bending force of the tendon on the bone.[474] This force could have been exerted by anyone, including the nurses, physiotherapists or the Plaintiff's family as they turned her to prevent bed sores or sat her up to prevent pneumonia.[475] But there is no evidence to show that the Plaintiff's family did not move the Plaintiff. *The Plaintiff has not eliminated the possibility that her family could have caused such injury* (*eg*, by testifying that they did not move the Plaintiff) *such that the injury could* ***only*** *have resulted from the Second Defendant's negligence*. If she had done so, the case for applying the doctrine of *res ipsa loquitur* would be stronger.

---

474 16/7/19 NE 79-81.

475 16/7/19 NE 86.

Version No 1: 27 Oct 2020 (22:41 hrs)

337 Counsel for the Second Defendant argued during oral closing submissions that *res ipsa loquitur* should not apply in medical negligence cases as there would be wide and significant implications to NUH. I disagree. Whether or not this legal principle applies depends largely on the facts of each case. The Second Defendant could have called its staff to rebut the claim of *res ipsa loquitur* if this claim is applicable. In my view, the Second Defendant is not exempted from *res ipsa loquitur* and the position is that stated in *Ratcliffe v Plymouth and Torbay Health Authority* [1998] PIQR P 170 ("*Ratcliffe*") at 184:

> It is now possible to draw some threads out of all this material, by way of explanation of the relevance of the maxim *res ipsa loquitur* to medical negligence cases:
>
> (1) In its purest form the maxim applies where the plaintiff relies on the '*res*' (the thing itself) to raise the inference of negligence, which is supported by ordinary human experience, with no need for expert evidence.
>
> (2) In principle, the maxim can be applied in that form in simple situations in the medical negligence field (surgeon cuts off right foot instead of left; swab left in operation site; patient wakes up in the course of surgical operation despite general anaesthetic).
>
> (3) ***In practice, in contested medical negligence cases the evidence of the plaintiff, which establishes the 'res', is likely to be buttressed by expert evidence to the effect that the matter complained does not ordinarily occur in the absence of negligence.***
>
> (4) The position may then be reached at the close of the plaintiff's case that the judge would be entitled to infer negligence on the defendant's part unless the defendant adduces evidence which discharges this inference.
>
> (5) ***This evidence may be to the effect that there is a plausible explanation of what may have happened which does not connote any negligence on the defendant's part.*** The explanation must be a plausible one and not a theoretically or remotely possible one, but the defendant certainly does not have to prove that his explanation is more likely to be correct than any other. If the plaintiff has no other evidence of negligence to rely on, his claim will then fail.
>
> (6) ***Alternatively, the defendant's evidence may satisfy the judge on the balance of probabilities that he did exercise proper care.*** If the untoward outcome is extremely rare, or is

Version No 1: 27 Oct 2020 (22:41 hrs)

> impossible to explain in the light of the current state of medical knowledge, the judge will be bound to exercise great care in evaluating the evidence before making such a finding, but if he does so, the prima facie inference of negligence is rebutted and the plaintiff's claim will fail. …
>
> (7) It follows from all this that ***although in very simple situations the 'res' may speak for itself at the end of the lay evidence adduced on behalf of the plaintiff, in practice the inference is then buttressed by expert evidence adduced on his behalf, and if the defendant were to call no evidence, the judge would be deciding the case on inferences he was entitled to draw from the whole of the evidence (including the expert evidence), and not on the application of the maxim in its purest form.***
>
> [original emphasis in italics; emphasis added in bold italics and bold underlined italics]

338 In this case, PW1 Ms Chiam had failed to testify that the Plaintiff's family did not reposition or move her when they assisted in the management of the Plaintiff whenever they visited her. Due to the Plaintiff's PVS, the hospital staff and the family members had to move the Plaintiff regularly so that she would not suffer from bedsores. There is no evidence to show that the Plaintiff's family members did not move or reposition her whenever they visited her at NUH. Thus, this must mean that the *res* did not speak for itself at the end of the Plaintiff's evidence (see points (3) and (7) of *Ratcliffe*, which corresponds to requirement (a) of *Rathanamalah* above).

339 The foregoing explains why I have concluded that *res ipsa loquitur* does not apply. The reasons are different from those urged upon me by the Second Defendant's counsel at the closing oral submissions. The Second Defendant emphasises that DW8 Prof Shamal's evidence is sufficient to rebut *res ipsa loquitur* as he had said that bedridden patients, such as the Plaintiff, are at risk of fractures even with normal handling. The fact that the Plaintiff had osteopaenia (a description of low bone density from the texture of the bone on

Version No 1: 27 Oct 2020 (22:41 hrs)

an X-ray) also put her at greater risk of developing fractures.[476] Finally, the fracture "can occur even when extraordinary care is taken".[477] However, at that point of the trial the court had yet to rule on whether *res ipsa loquitur* even applied (*ie*, point (3) of *Ratcliffe*). It is very unfortunate that the Defendants did not call any nurses to testify whether proper, or extraordinary, care was given to the Plaintiff. If the Plaintiff had deteriorated to the extent of being extraordinarily fragile, it would be incumbent on the Second Defendant to realise this and exercise special care. There is no evidence on the level of care that was actually given. DW8 Prof Shamal was giving evidence from an expert perspective even though he was called as a factual witness, because he was not involved in the care and management of the Plaintiff before the fracture was discovered. DW8 Prof Shamal's opinion suggested that injuries similar to the Plaintiff's fracture would have occured with the best of care. If that is correct, one would have expected more instances of such injury between August 2016, the year the Plaintiff sustained the injury, and May 2017 when the writ was filed. Since no similar injury was pleaded, the inference is that there was none. Thus DW8 Prof Shamal's opinion is not supported by the evidence. In my view, it is incumbent upon the hospital to provide special and bespoke medical care that is tailored to the needs of each patient. It cannot provide one-size-fits-all patient care. In other words, if a patient requires special care because of brittle bones then the hospital is duty-bound to provide special care that befits him as normal care may not have met the standard of care for such patient. There was simply no evidence of this.

---

476 DW8 Prof Shamal Das De's AEIC at para 12; 16/7/19 NE 98.

477 D2CS at para 184.

Version No 1: 27 Oct 2020 (22:41 hrs)

340 To summarise, I conclude that the Plaintiff is not entitled to any remedies for the fracture. *Res ipsa loquitur* does not apply and the Plaintiff has not proven the Second Defendant's negligence in this regard.

The Second Defendant's counterclaim

341 I allow the Second Defendant's counterclaim for S$397,478.78 as of 26 July 2019 and further hospital bills from 27 July 2019 to the date of judgment. This follows from my finding that the Defendants were not negligent.

Conclusion

342 The Plaintiff's symptoms before the First Surgery, namely dizzy spells, hearing impairment in her left ear, walking difficulties and problems in balancing which led to a few falls, did not seem serious to a lay person. After a successful surgery, the world of the Plaintiff and her family was turned upside down. Suddenly, she was and is still in a PVS. This is tragic and it is understandable that the Plaintiff's family finds it tremendously difficult to accept the dreadful outcome. I deeply empathise with the frustration and disappointment of the Plaintiff's family towards the surgical team led by the First Defendant. But justice must be meted out according to the rule of law and not the feelings of the heart in order to reach a fair outcome based on the merits and facts of this case. I would like to convey my heartfelt sympathy to the Plaintiff and her family. I hope, one day, a miracle will wake up the Plaintiff from her deep slumber like the case of the mother in the UAE that I have cited above.

343 To summarise, I dismiss the Plaintiff's claim because:

Version No 1: 27 Oct 2020 (22:41 hrs)

(a) The First Defendant was not negligent at the pre-operative stage and so the Second Defendant cannot be vicariously liable.

(b) At the post-operative stage, the Second Defendant did not fall below the requisite standard of care in terms of monitoring the Plaintiff's parameters and/or omitting to order a CT scan at 1655 hrs or 1730 hrs. The First Defendant was not negligent in coming to the view that her prognosis was poor, due to the presence of an intra-axial pontine haematoma as seen from the First CT Scan. He was also not negligent in only inserting an EVD without evacuating the extra-axial haematoma. He and his team were not negligent in the taking of informed consent from PW1 Ms Chiam for the Second Surgery. They did not breach their duty of care for not advising PW1 Ms Chiam on the alternative option of evacuating the haematoma.

(c) The Second Defendant is not liable for the fracture of the tibial tuberosity suffered by the Plaintiff.

Version No 1: 27 Oct 2020 (22:41 hrs)

344 Following from this, I allow the Second Defendant's counterclaim for S$397,478.78 as of 26 July 2019 and further hospital bills from 27 July 2019 to the date of judgment. The Plaintiff will pay to the Defendants the costs of these proceedings which will be agreed or taxed.

Tan Siong Thye
Judge

Abraham Vergis and Bestlyn Loo (instructed) (Providence Law Asia LLC), Seenivasan Lalita, Virginia Quek and Isabel Chew (Virginia Quek Lalita & Partners) for the Plaintiff;
Lek Siang Pheng, Mar Seow Hwei, Aw Sze Min and Toh Cher Han (Dentons Rodyk & Davidson LLP) for the First Defendant;
Kuah Boon Theng SC, Yong Shuk Lin Vanessa and Chain Xiao Jing, Felicia (Qian Xiaojing) (Legal Clinic LLC) for the Second Defendant.

Version No 1: 27 Oct 2020 (22:41 hrs)